

## Effect of Ascorbic Acid on Hemato-Histopathological changes induced by Diclofenac Sodium in local Male Rabbits

Mohammed Abed Mahmood

Department of Pathology, Faculty of Veterinary  
Medicine, University of Diyala, Iraq

Correspondence E-mail: [mohammedvet87@gmail.com](mailto:mohammedvet87@gmail.com)

### Abstract

**Background** :Diclofenac sodium is non-steroidal anti-inflammatory analgesic drug, It is widely used in the world.

**Aims**: to identify effect of ascorbic acid (Vitamin C) on haematological and histopathological changes induced by diclofenac sodium.

**Methods**: Fifteen local male rabbits divided equally and randomly into three groups, each group five rabbits. First group (control group) injected intramuscularly with normal saline (9% NaCl) for 14 days. Second group injected intramuscularly with diclofenac sodium (1.5 mg/kg of BW) daily for 14 days. Third group injected intramuscularly with ascorbic acid (150 mg/kg of BW), after two hours injected intramuscularly with 1.5 mg/kg of B.W of diclofenac sodium for 14 days.

**Results**: Diclofenac sodium caused significant decrease ( $p < 0.05$ ) of hematocrit percentage, haemoglobin concentration and platelets count, significant increase of reticulocytes. White blood cells, neutrophil showed significant decrease ( $p < 0.05$ ). The histopathological changes include alteration in liver tissue including dilation of sinusoid, intracytoplasmic vacuolation, congestion of sinusoids and little fatty changes. Kidney in second group showed mononuclear cell infiltrations, dilation of proximal convoluted tubule, expanded of glomeruli and focal tubular necrosis. In third group, the used of ascorbic acid lead to correction of haematological parameters variation and histopathological changes, this may be result from antioxidant activity of ascorbic acid to scavenger of free radicle and restricted of toxicity of diclofenac sodium.

**Keywords**: Diclofenac sodium, ascorbic acid, RBC,WBC, histopathology.



This is an open access article licensed under a [Creative Commons Attribution- NonCommercial 4.0 International License](https://creativecommons.org/licenses/by-nc/4.0/).

## Introduction

In veterinary medicine, the medical uses of pain inhibitor especially diclofenac sodium or voltaren (trade name) are limited because of decrease the full information of voltaren in the all species and types of animal and natural of pharmacokinetics in body of it, the most previous study of diclofenac sodium in animal restricted on accidental causes, inflammatory lesion and lameness in horse [1], One of important dietary sources for human and carnivorous animal are rabbits meat because of cheap price, high nutritional value which contain high protein with low ratio of cholesterol [2]. Diclofenac sodium (Voltaren) is non-steroidal anti-inflammatory drug; it was used primarily for treatment of chronic disease such as osteoarthritic [3],

Osteoporosis, acute and chronic diseases in addition to use as antipyretic and treatment of migraines [4],[5],[6] Despite the therapeutic benefits of this drug, its use is not without side effects and toxicity and these effects appearance on the various tissues and organs of the body, it was found that the drugs cause risks for the heart , cardiovascular vessels , ulcer in stomach and intestine [7],[8],[9]. Diclofenac sodium consider inhibitor drug for cyclooxygenase that lead to histopathological effect on the stomach [10] and other researchers mention the diclofenac causes histopathological changes in the tissues in the human and rabbits [11].The rabbits fertility also affected and pathological lesions in some tissue of female reproductive tissues [12].Liver consider more organ under dangerous of different drugs during the cycling of drug in the body and the toxicity is still poor when comparable the animal with human ,diclofenac sodium or voltaren used to remove or decrease pain in animals [13], and has antibacterial activity when administration in rabbits [14]. some researchers recorded skin and skeletal muscle disorders while other

mention the diclofenac as anti- carcinogenic drug in the rabbits [15],[16]. In other side, some female rabbits showed abnormal signs when injected intraperitoneally by diclofenac sodium, these signs include increase of prolactin , L H hormone levels and increase body weight duo to high level of sugar in blood [17]. Diclofenac is longer action in rabbits than paracetamol but become toxic in overdoses and some time lead to hepatotoxicity and other study reported the effects of diclofenac sodium on the GIT including edema in stomach mucosa in addition to nervous effect in the rabbits [18],[19].

this study deal with the hematological and histopathological effects of diclofenac sodium on the liver and kidney and Role of ascorbic acid (vitamin C) to minimize these changes in liver and kidney in rabbits.

## Material and Method

In this study, fifteen (local strain) rabbits, 3-month-old age, (1.5) kg weight. Rabbits were placed in cages with dimensions (46, 44, and 62) cm, with 5 rabbits in each cage inside an air-conditioned room at a temperature (22-25) C and lighting by 12 hours of light per day and fed well.

**Experimental design:** Rabbits classified into three group:

**First group (control group):** injected daily with normal saline for 14 days.

**Second group ( Diclofenac sodium group):** injected one dose daily with diclofenac sodium ampule (1.5 mg/kg of B.W) for 14 days.

**Third group:** injected firstly with vitamin C (150mg/kg of B.W) one dose daily and after two hours injected with diclofenac sodium

(1.5 mg/kg of BW) one dose daily for 14 days.

**Route of injection:** was intramuscular injection.

**Drug:** Diclofenac sodium ampoules for intramuscular injection from Indian company for pharmaceutical industries and ascorbic acid (vitamin C) made in Bayer company (Jerman).

**Hematological preparation for analyzer:** In this experimental study EDTA tube used for collection of blood samples, Hematological analyser used for identify the RBC , WBC , hemoglobin platelets counts and other hematological parameters.

**Histopathological study:** The liver and kidney samples of rabbits fixed in 10% natural buffer formalin, then dehydrated in 70, 85, 95 and 100 subsequent concentration of ethanol, cleared in two steps of xylol and embedded in three steps of molted paraffin (58°C), section by microtome in 5 mm and stain by hemotoxylin and eosin stain for microscopic examination [20].

**Statistical analysis:** The data, unless otherwise noted, is expressed as mean SEM.

The ANOVA statistical analysis method was used. The cutoff for a meaningful difference was  $P < 0.05$ .

## Results

The second diclofenac sodium group showed significant increase in reticulocytes value ( $p < 0.05$ ) and significant decrease ( $p < 0.05$ ) in concentration of hemoglobin (Table 1). The platelets not showed significant differences ( $p > 0.05$ ) in treated second group compared with control group. The third group (vitamin C with diclofenac sodium) not showed significant variation ( $p > 0.05$ ) and the values similar to in the control group (Table 1) H.

Second treated group not showed significant

decrease in white blood cells ( $p > 0.05$ ) comparable with control group. The lymphocytes showed significant increase ( $p < 0.05$ ) and neutrophils showed significant decrease ( $p < 0.05$ ) comparable with control group. Eosinophil and monocytes not showed significant variation ( $p > 0.05$ ) than control group. The third group (vitamin C with diclofenac sodium) not showed significant variation ( $p > 0.05$ ) and the values similar to in the control group (Table 2).

Table 1 showed parameters of RBC and platelets in control , diclofenac sodium and (ascorbic acid & diclofenac sodium group)  $p<0.05$ .

Parameter	Control group	Diclofenac group	Ascorbic acid & diclofenac group
Hematocrit %	43.5±1.101	38.08±1.201*	42.5±1.101
Hemoglobin concentration	13.4±0.5	11.02±0.4*	13.1±0.5
Reticulocyte %	2.26±1.219	5.766±1.119*	2.27±1.119
Platelet count cell/I	338.4±26.31	325.88±25.31	336.4±26.31

Table 2: showed parameters of White blood cells in control , diclofenac sodium and (ascorbic acid & diclofenac sodium group)  $p<0.05$ .

Parameters %	Control g.	Diclofenac sodium g.	Ascorbic acid & diclofenac sodium g.
Wbc	5520±384.23	4950±384.23	5320±374.23
Neutrophils	56.8±2.438	43.36±2.438*	55.8±2.522
Eosinophils	2 ±0.5	1.54 ±0.5	2 ±0.3
Monocytes	3.5 ±0.6	3.22 ±0.3	3.5 ±0.4
Lymphocytes	31.2±2.23	48.53 ±2.33*	32.2±2.33

Diclofenac sodium effect on red blood cells by showed significant increase ( $p > 0.05$ ) in reticulocytes comparable with control group and third group (ascorbic acid & diclofenac sodium) by increased in percentage during 14 days (chart 1) with no significant differences of blood platelets in second group comparable with control and third group (ascorbic acid & diclofenac sodium group), (chart 2).

significant decrease ( $p < 0.05$ ) in second diclofenac sodium comparable with control and third group (ascorbic acid & diclofenac sodium group) at 14 days (chart 1).

The hemoglobin and hematocrit showed

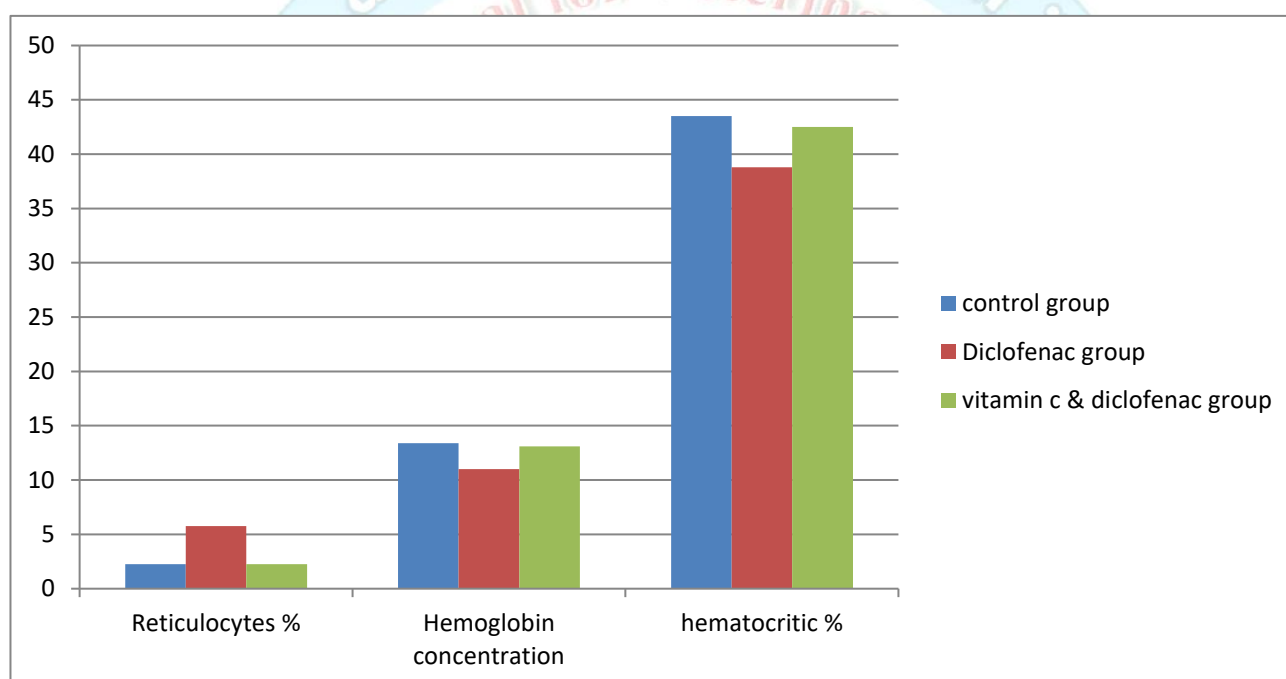


chart 1 showed values of Reticulocytes, Hemoglobin concentration and hematocritic between three experimental groups.

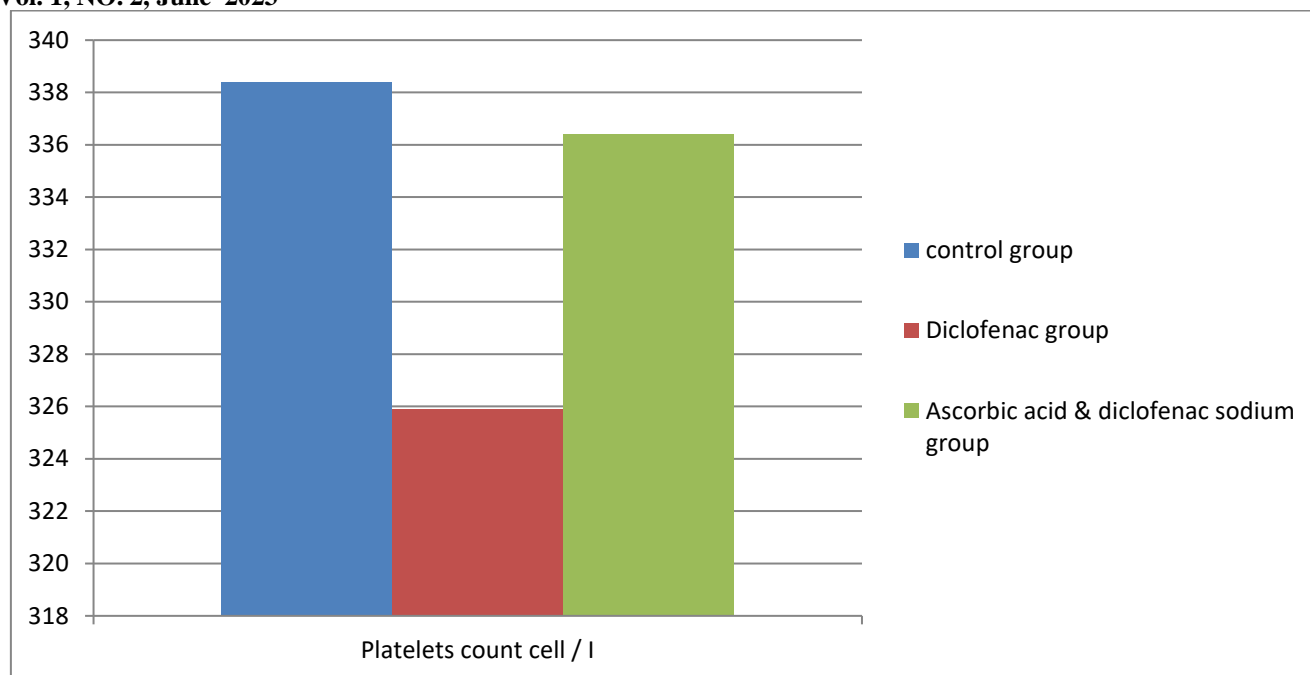


chart 2 showed significant differences of Platelets between three experimental groups.

Also, the diclofenac sodium effected on white blood cells which not showed significant differences between three comparable group ( $p > 0.05$ ), (chart 3). Neutrophils and eosinophils showed significant decrease ( $p < 0.05$ ) while the lymphocytes and monocytes showed significant increase ( $p < 0.05$ ) than control groups (chart

4&5).

The third group (Ascorbic acid followed by diclofenac sodium) lead to return of the Red blood cells and white blood cells to the normal after changes which effected by injection of diclofenac sodium

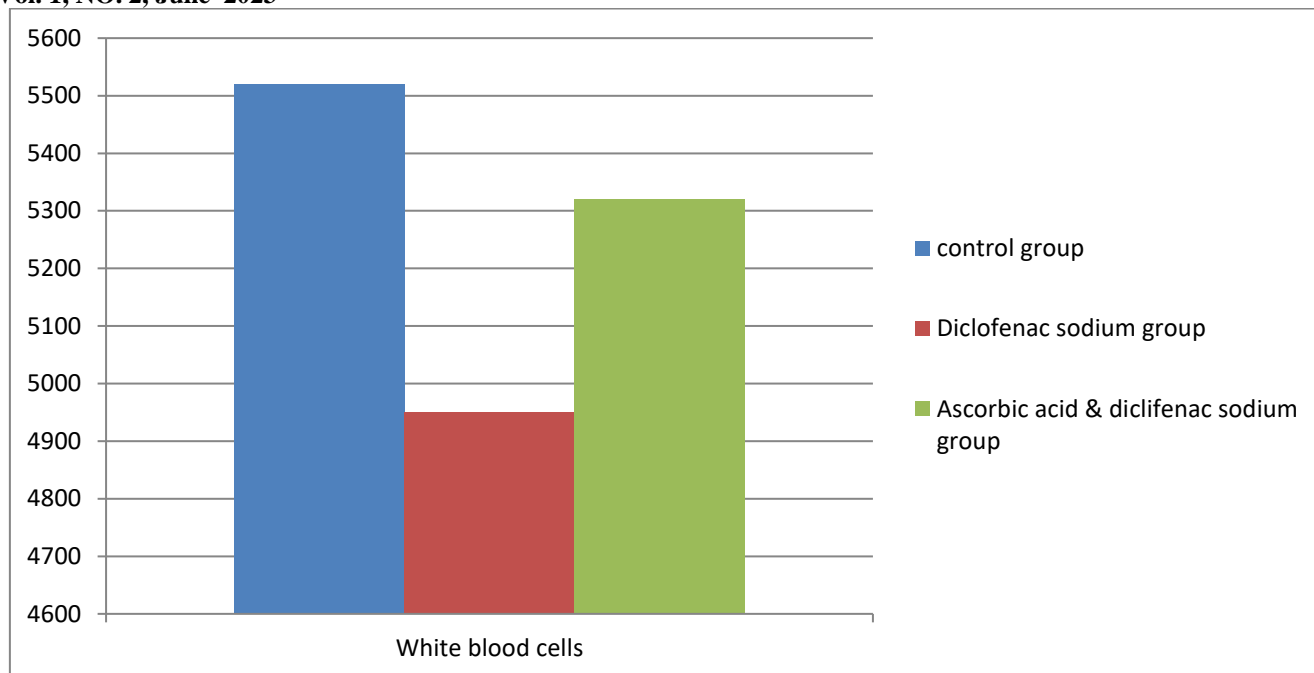


chart 3 showed significant differences of WBC between three experimental groups.

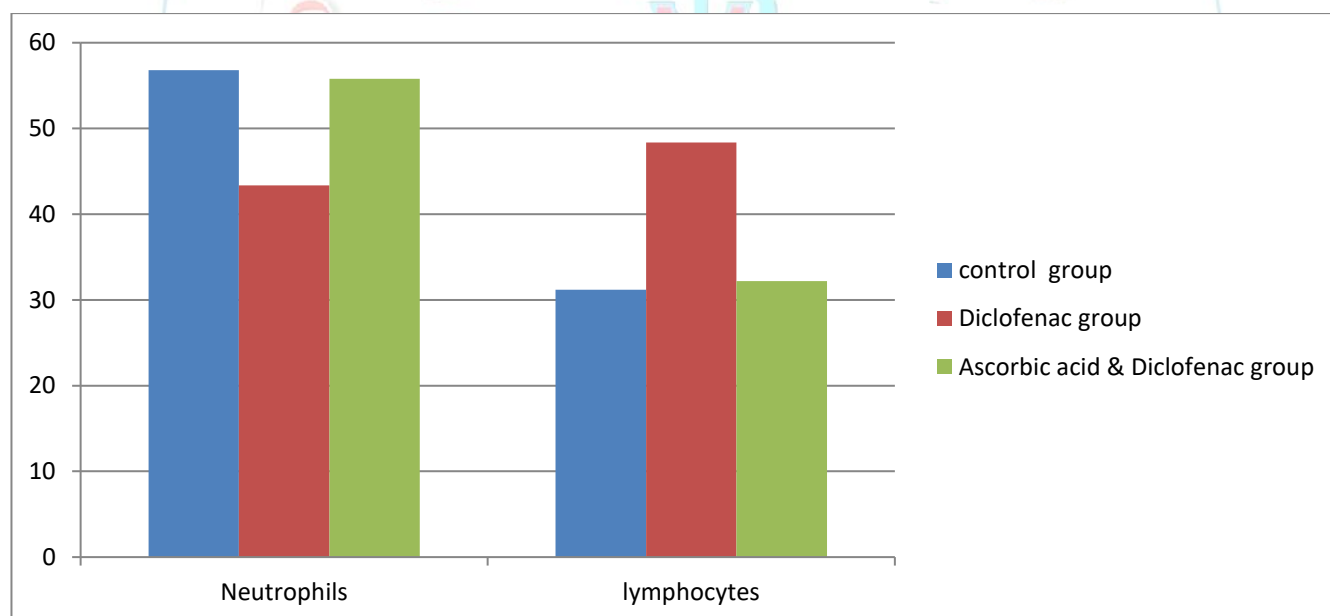


chart 4 showed significant differences of neutrophils and lymphocytes between three experimental groups.

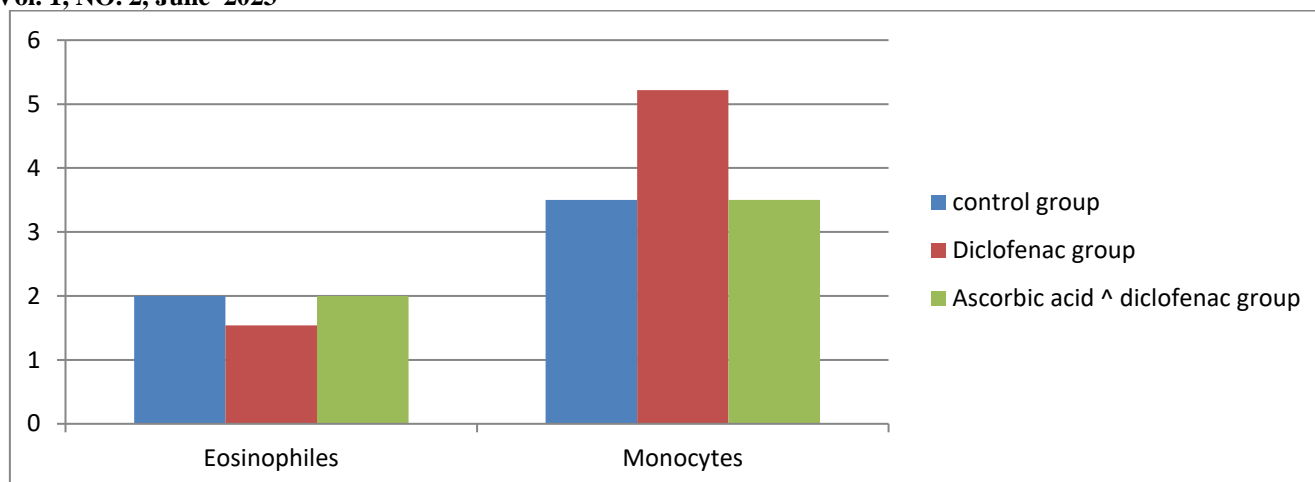


chart 5 showed significant differences of eosinophils and monocytes between three experimental groups.

### Histopathological results

The liver in control group showed normal central vein, normal lobule, normal portal system in addition normal bile duct, sinusoid and connective tissue (figure 1). The second group treated with two dose daily with diclofenac sodium ampule (1.5 mg/kg of B.W) for 14 days, that showed alteration in liver tissue including dilation of sinusoid, intracytoplasmic vacuolation, congestion of sinusoids and little fatty changes (figure 2). Liver showed in third group which injected firstly with vitamin C (150mg/kg of B.W) one dose daily and after two

hours injected with diclofenac sodium (1.5 mg/kg of BW) one dose daily for 14 days normal tissue architecture (Figure 3).

Kidney in control group showed normal histological architectures (figure 4), but the kidney in second group (treated with diclofenac sodium twice daily for two weeks) showed mononuclear cell infiltrations, dilation of proximal convoluted tubule, expanded of glomeruli and focal tubular necrosis (figure 5). Tired group (ascorbic acid & diclofenac sodium for two weeks) the kidney showed normal glomeruli and tubules (figure 6).

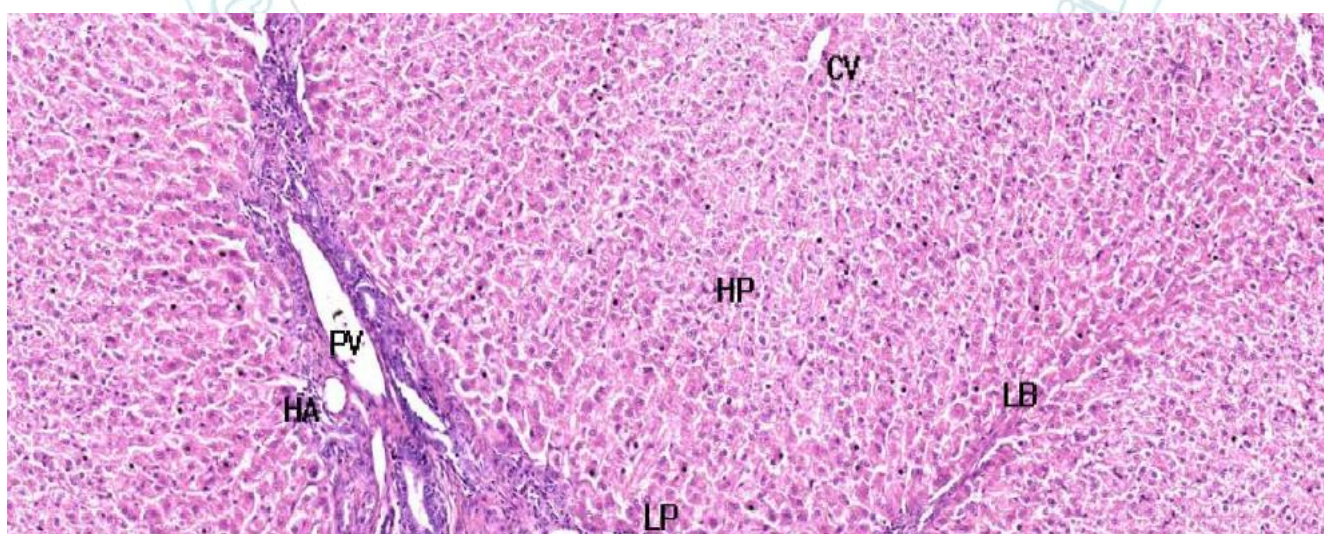


Figure 1. Photomicrograph of liver in control group showed normal central vein (CV), limit plate (LP),



hepatic parancheyma (HP), portal vein (PV), hepatic artery (HA) lobule band (LB), H&E stain 40X.

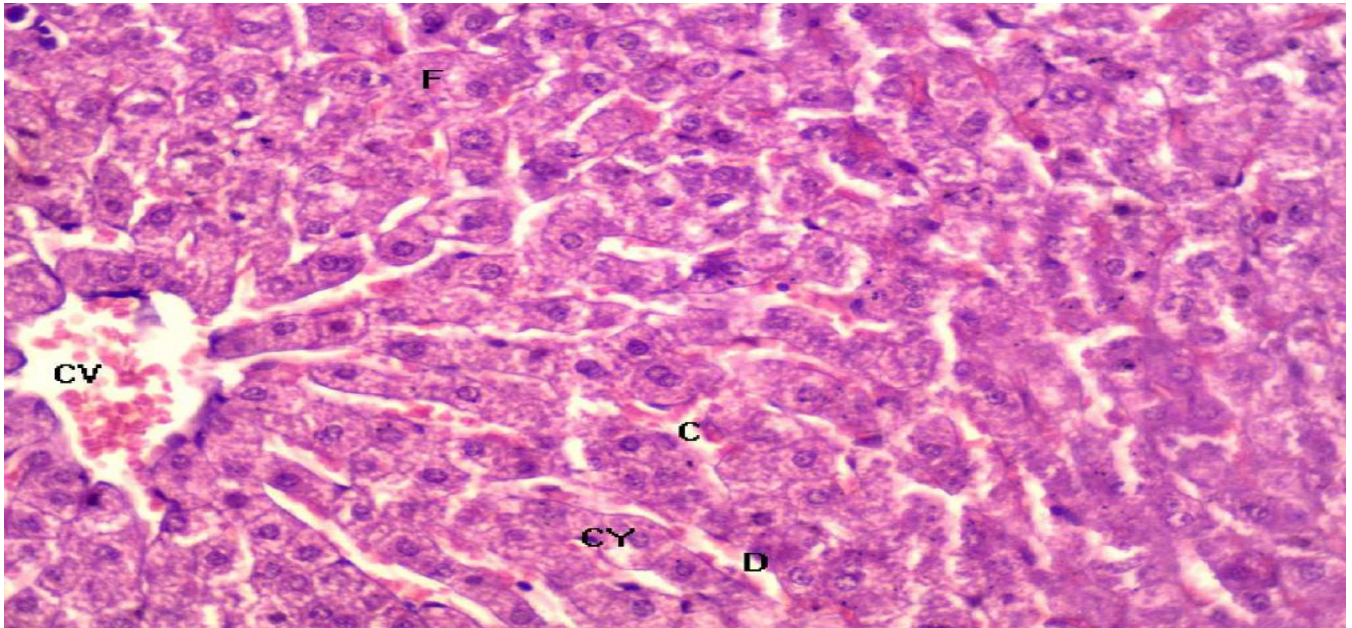


Figure 2. photomicrograph of liver belong to second treated group showed cytoplasmic vacuole (CY), congestion (C) , little fatty changes (F) and dilation of sinusoids H&E stain 40X.

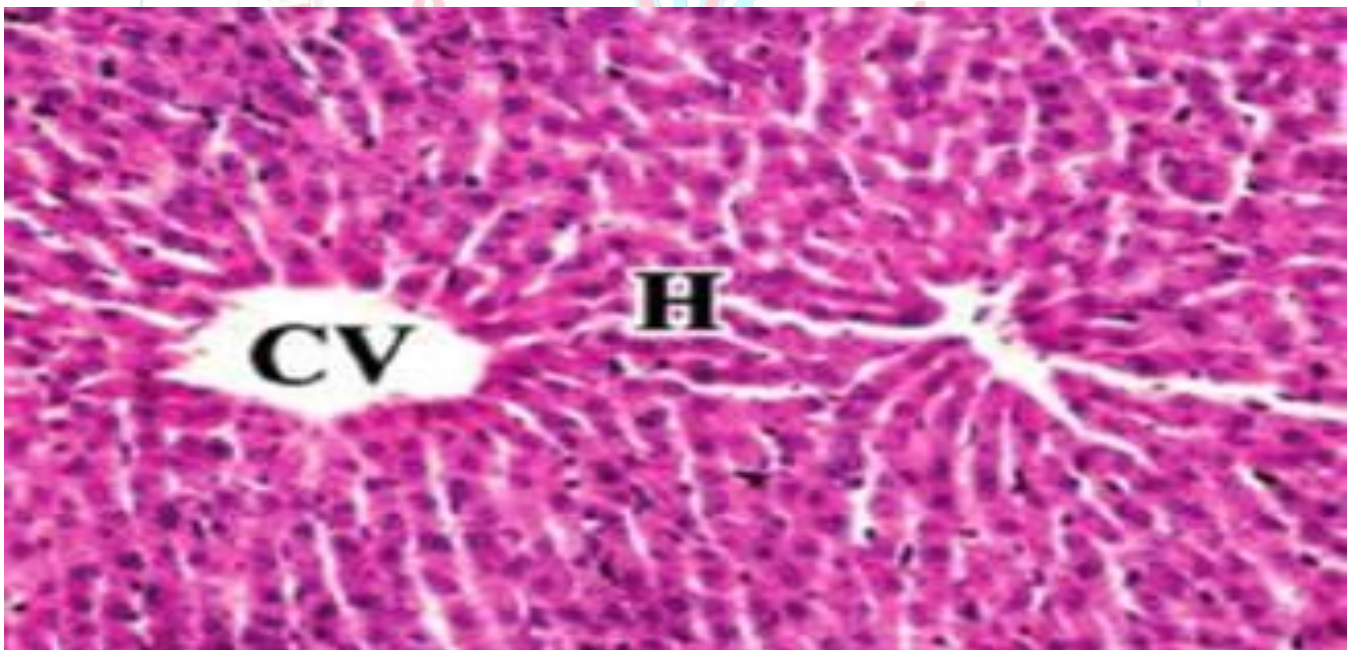


Figure 3. Photomicrograph of liver of third group (ascorbic acid & diclofenac sodium) showed normal central vein (CV) and hepatocytes, H&E stain 40X.

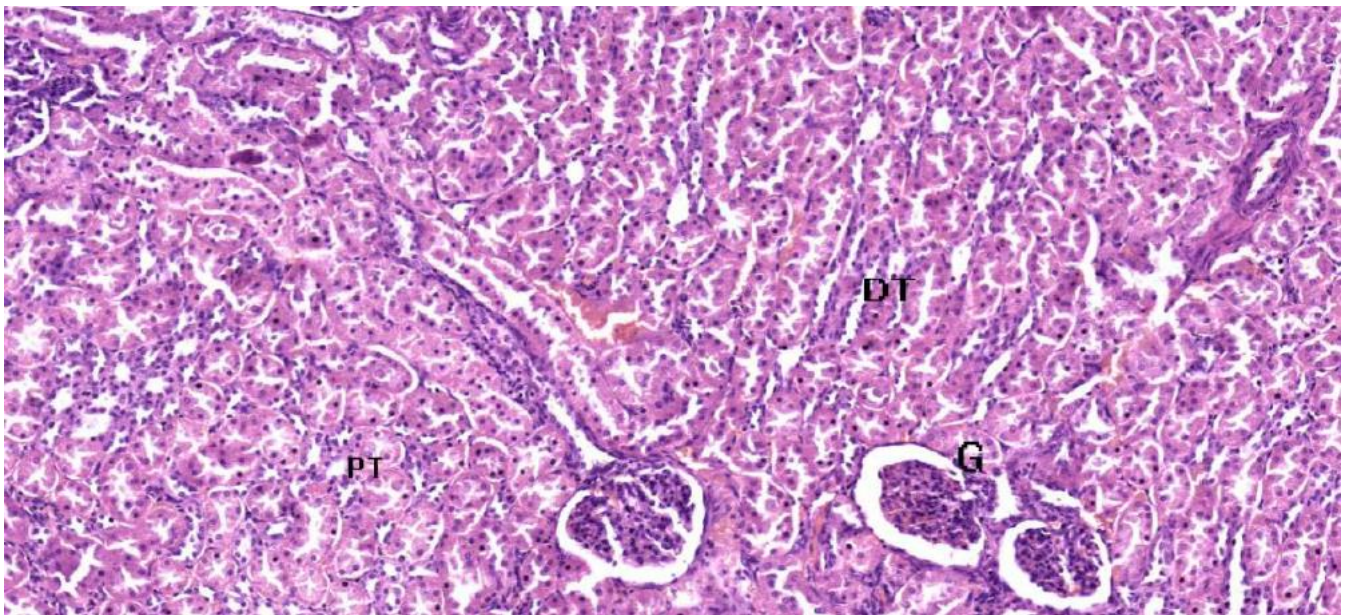


Figure 4. photomicrograph of kidney belong to control group showed normal histological of kidney include glomeruli (G), proximal convoluted tubule (PT) and distal convoluted tubule (DT), H&E stain 40X.

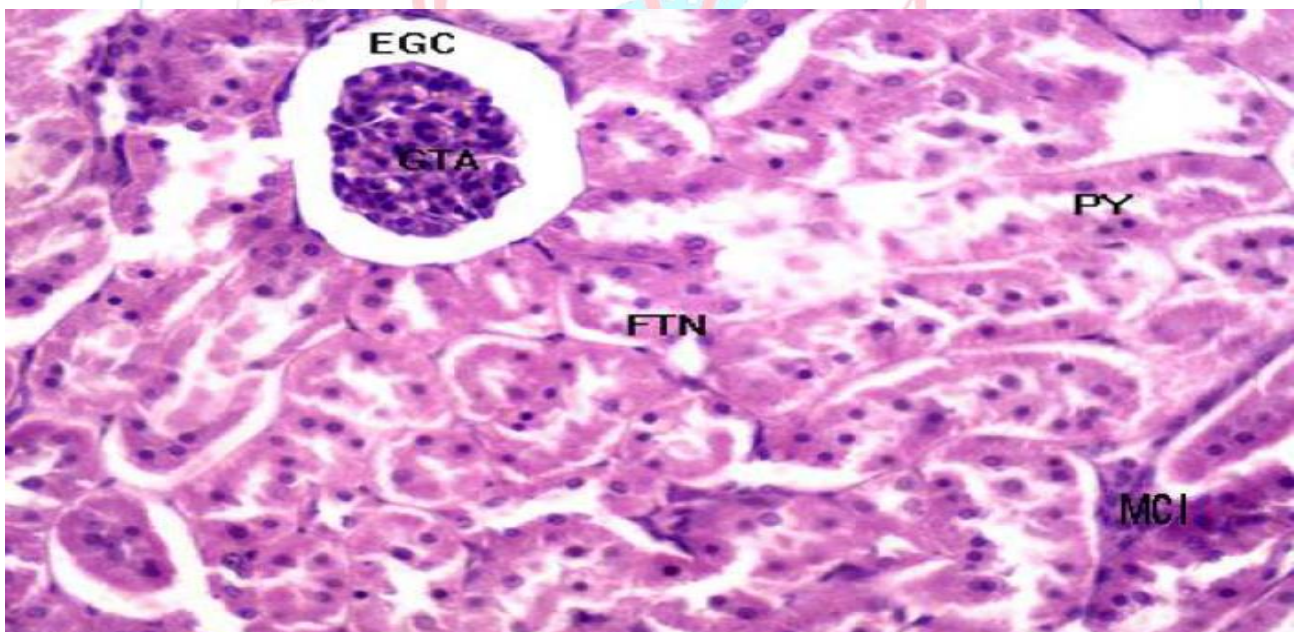


Figure 5. photomicrograph of kidney belong to second treated group showed mononuclear cells **infiltrations** (MCI), dilation of proximal tubule (PY), expanded of glomerular chambers (EGC) and focal tubular necrosis (FTN), H&E stain 100X.

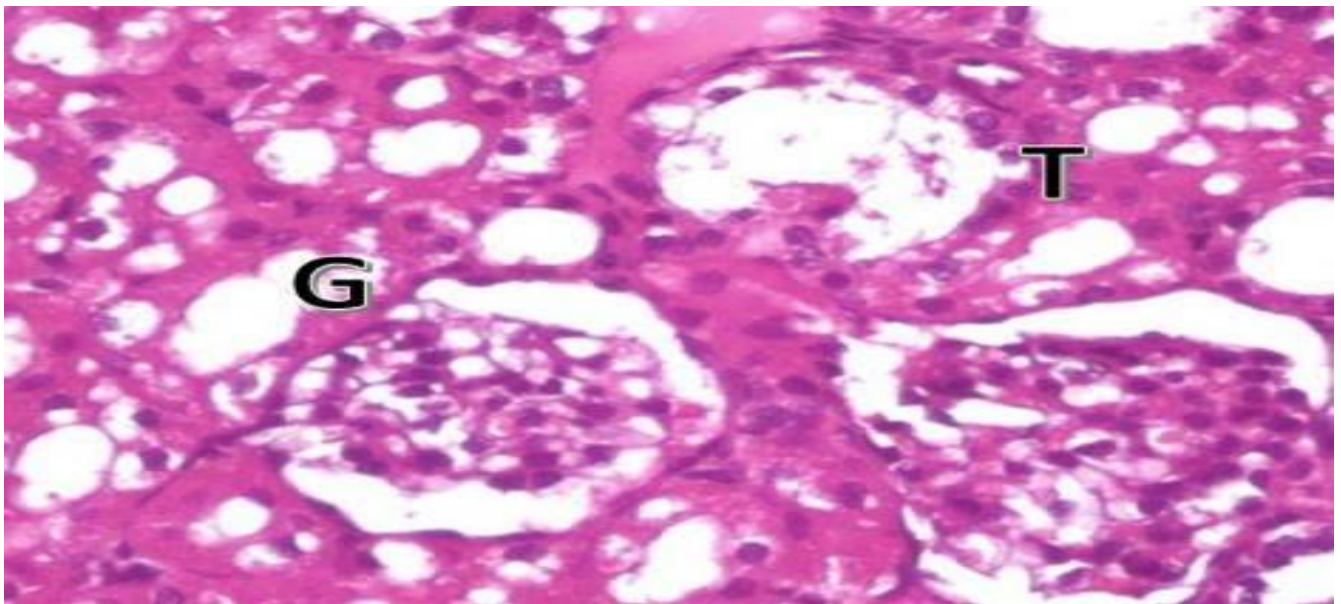


Figure 6. photomicrograph of kidney belong to third treated group (ascorbic acid & diclofenac sodium) showed normal glomeruli (G) and tubules (T) H&E stain 100X.

## Discussion

Diclofenac sodium consider one of important choice drug for relieving pain by prevent synthesis of PGE and anti-inflammatory drug in worldwide [21]. With beneficial effect of diclofenac sodium, this drug if uses for long term may be causes harmful effect on the different body specially liver and kidney [22]. In this study, diclofenac sodium causes alteration in hematological parameters by decrease the hemoglobin concentration and percentage of hematocrit comparable with control group in addition to significant increase of reticulocytes, this result similar to study by [23] which sure hemolytic anemia which caused by diclofenac sodium lead to produce antibody against RBCs but in same study the diclofenac sodium not consider antibody. The hemolytic anemia may be duo to cellular immunity by increase lymphocytes as in this study [24] but in the same time , the diclofenac sodium correction hemoglobin concentration and this agreement with [25]. White blood cells also effected by diclofenac sodium which causes decrease of neutrophils and this agreement with [26] which said the diclofenac sodium causes neutropenia

and the [27] which mentioned the diclofenac may responsible for decrease of neutrophil. In this study the diclofenac sodium caused increase of lymphocytes and this sure by [28] which mentioned the diclofenac sodium caused lymphocytosis when given different doses of drug in rats. But this disagreed with [29] and this may be belong to different of species and dose of drug when the experimental study performed on dogs. In this study, the monocytes and eosinophil become normal and there is no any signs of allergy recorded by this study. The histopathological study of second group showed cytoplasmic vacuole, congestion and little fatty changes in addition to dilation of sinusoids and this agree with [28] which recorded same lesion when uses different doses of diclofenac sodium on the rats. In 2013 the [30] recorded of congestion in the liver, vacuolation and necrosis when injection of diclofenac sodium for 3 weeks in rats. [31] reported same pathological lesion on the liver including sever necrosis, mononuclear cells infiltrations in birds. In this study, the kidney in treated second group showed mononuclear cells infiltrations, dilation

of proximal tubules, expansion of glomeruli and necrosis, this study agreement with [32]. In this study, the ascorbic acid (vitamin C) lead to protective the histological structures of liver and kidney from effect of diclofenac sodium, this may be due to role of ascorbic acid which neutralize reactive oxygen species and free radical scavenger [33]. Also the study which show role of antioxidant in combination with anti-inflammatory drug is still little. Ascorbic acid lead to return the percentage of hematocrit and hemoglobin concentration to normal in comparable with control group which decreased by effect of diclofenac sodium, this agreement with [34] when performed study on the human. Reticulocytes showed elevated in second group but in third group back to normal and same think on the platelets count concentration, this study is disagree with other study by [35] on the human which reported increase hemoglobin concentration when recurrent uses of ascorbic acid, this may be belong to different the species and dose of antioxidant. White blood cells showed different value when used of ascorbic acid including neutrophils, WBC, basophils, eosinophil, monocytes and lymphocytes, in this study there is slightly decrease in neutrophils in second group and relatively increase in the lymphocytes [36]. This study agreement with [37] which mentioned occurrence of renal damage after diclofenac sodium injection daily. Ascorbic acid lead to preservative histology of liver and kidney, this may lead to antioxidant effect of vitamin C on voltaren and the ascorbic acid restricted the toxic effect of diclofenac sodium and this may be agreement with study in 2010 by [38] when said the vitamin C restricted toxicity of endosulfan because of prevent accumulation of toxic material in rabbits. Ascorbic acid with combination of nigella sativa lead to restricted the histopathological changes caused by gentamicin [39] and this agreement with this study.

### Conclusion

The current study showed the diclofenac sodium lead to decrease of hematological parameters in addition to histological changes on the liver and kidney while the ascorbic acid lead to return these parameters value to the normal.

### Conflict of Interests

The authors declare no conflict of interest.

### Funding statements

This study was totally supported by Pathological department, College of Veterinary Medicine University of Diyala.

**References**[1] J. J. Bertone, R. C. Lynn, N. J. Vatistas, W. J. Kelch, R. L. Sifferman, and D. I. Hepler, "Clinical field trial to evaluate the efficacy of topically applied diclofenac liposomal cream for the relief of joint lameness in horses," *48th Proc. Am. Assoc. Equine Pract.*, pp. 190–193, 2002.

[2] A. Dalle Zotte *et al.*, "Dietary Spirulina (*Arthrospira platensis*) and Thyme (*Thymus vulgaris*) supplementation to growing rabbits: Effects on raw and cooked meat quality, nutrient true retention and oxidative stability," *Meat Sci.*, vol. 98, no. 2, pp. 94–103, 2014.

[3] N. Bellamy, W. G. Bensen, P. M. Ford, S. H. Huang, and J. Y. Lang, "Double-blind randomized controlled trial of flurbiprofen-SR (ANSAID-SR) and diclofenac sodium-SR (Voltaren-SR) in the treatment of osteoarthritis.," *Clin. Invest. Med.*, vol. 15, no. 5, pp. 427–433, 1992.

[4] B. B. Turkoski, "New medications and medication changes," *Orthop. Nurs.*, vol. 27, no. 5, pp. 318–320,

[5] P. Gehanno, R. L. Dreiser, E. Ionescu, M. Gold, and J.-M. Liu, "Lowest effective single dose of diclofenac for antipyretic and analgesic effects in acute febrile sore throat," *Clin. Drug Investig.*, vol. 23, no. 4, pp. 263–271, 2003.

[6] H. C. Diener *et al.*, "Efficacy and tolerability of diclofenac potassium sachets in migraine: a randomized, double-blind, cross-

over study in comparison with diclofenac potassium tablets and placebo,” *Cephalalgia*, vol. 26, no. 5, pp. 537–547, 2006.

[7] K. H. Maniar, I. A. Jones, R. Gopalakrishna, and C. T. Vangsness Jr, “Lowering side effects of NSAID usage in osteoarthritis: recent attempts at minimizing dosage,” *Expert Opin. Pharmacother.*, vol. 19, no. 2, pp. 93–102, 2018.

[8] B. Hinz, H. Dormann, and K. Brune, “More pronounced inhibition of cyclooxygenase 2, increase in blood pressure, and reduction of heart rate by treatment with diclofenac compared with celecoxib and rofecoxib,” *Arthritis Rheum. Off. J. Am. Coll. Rheumatol.*, vol. 54, no. 1, pp. 282–291, 2006.

[9] S. K. Goswami *et al.*, “Anti-ulcer efficacy of soluble epoxide hydrolase inhibitor TPPU on diclofenac-induced intestinal ulcers,” *J. Pharmacol. Exp. Ther.*, vol. 357, no. 3, pp. 529–536, 2016.

[10] J. L. Wallace, B. Reuter, C. Cicala, W. McKnight, M. Grisham, and G. Cirino, “A diclofenac derivative without ulcerogenic properties,” *Eur. J. Pharmacol.*, vol. 257, no. 3, pp. 249–255, 1994.

[11] T. J. Moskal, “Minimizing the risk factors associated with veterinary NSAIDs,” *J. Am. Vet. Med. Assoc.*, vol. 224, no. 8, pp. 1231–1232, 2004.

[12] P. Toxemia *et al.*, “Disorders of the Reproductive and Urinary Systems,” *Ferrets, Rabbit. Rodents-e-b. Clin. Med. Surg.*, p. 217, 2011.

[13] Y. Talat, S. I. Ashraf, A. Zaheer, S. Amir

Ali, and M. Talat, “Alterations in mitochondria of kidney tubules by different doses of diclofenac sodium in rabbits,” 2014.

[14] S. Z. Krustev, N. V. Rusenova, and A. M. Haritova, “Effect of diclofenac on ocular levels of ciprofloxacin and lomefloxacin in rabbits with endophthalmitis,” *Drug Dev. Ind. Pharm.*, vol. 40, no. 11, pp. 1459–1462, 2014.

[15] G. Kantarcı, I. Özgüney, H. Y. Karasulu, T. Güneri, and G. Başdemir, “In vitro permeation of diclofenac sodium from novel microemulsion formulations through rabbit skin,” *Drug Dev. Res.*, vol. 65, no. 1, pp. 17–25, 2005.

[16] M. K. Saini, J. Kaur, P. Sharma, and S. N. Sanyal, “Chemopreventive response of diclofenac, a non-steroidal anti-inflammatory drug in experimental carcinogenesis,” *Nutr. Hosp.*, vol. 24, no. 6, pp. 717–723, 2009.

[17] A. S. Siddig, A. A. Ismail, and B. A. Mohammed, “Effect of medications misused for body weight gain on sodium and potassium concentration of female rabbits,” *GSC Biol. Pharm. Sci.*, vol. 2, no. 1, 2018.

[18] N. T. Taib and B. M. Jarrar, “Histochemical alterations in the spleen of rabbits induced by diclofenac sodium (Voltaren),” *J King Saud Univ. Sci.*, vol. 19, p. 21, 2006.

[19] H. Suleyman, B. Demircan, and Y. Karagoz, “Anti-inflammatory and side effects of cyclo-oxygenase inhibitors,” *Pharmacol. reports*, vol. 59, no. 3, p. 247, 2007.

[20] L. G. Luna, “Manual of histologic staining methods of the Armed Forces Institute

of Pathology,” 1968.

[21] M. Moussa, A. G. Papatsoris, and M. Abou Chakra, “Intradermal sterile water injection versus diclofenac sodium in acute renal colic pain: a randomized controlled trial,” *Am. J. Emerg. Med.*, vol. 44, pp. 395–400, 2021.

[22] G. Shams, “Residues of Diclofenac Sodium in Rabbit Tissues,” *Zagazig Vet. J.*, vol. 47, no. 3, pp. 298–305, 2019.

[23] I. Ahmad *et al.*, “Hematological effects of diclofenac sodium in goat,” *J. Anim. Plant Sci.*, vol. 23, no. 1, pp. 103–107, 2013.

[24] F. Izak-Shirian *et al.*, “Quercetin exerts an ameliorative effect in the rat model of diclofenac-induced renal injury through mitigation of inflammatory response and modulation of oxidative stress,” *Eur. J. Inflamm.*, vol. 20, p. 1721727X221086530, 2022.

[25] A. Iftikhar, I. J. Hasan, M. Sarfraz, L. Jafri, and M. A. Ashraf, “Nephroprotective effect of the leaves of *Aloe barbadensis* (Aloe Vera) against toxicity induced by diclofenac sodium in albino rabbits,” *West Indian Med. J.*, vol. 64, no. 5, p. 462, 2015.

[26] M. A. J. Al-Saady, A. Abdul-Latif, and H. N. Al-Shemmary, “Pharmacological effects of diclofenac sodium on some haematological parameters of male rabbits,” *Med J Babyl*, vol. 8, no. 3, pp. 441–452, 2011.

[27] B. R. Curtis, “Drug-induced immune neutropenia/agranulocytosis,” *Immunohematology*, vol. 30, no. 2, pp. 95–101, 2014.

[28] G. Aydin, A. Gökçimen, M. Öncü, E. Çicek, N. Karahan, and O. Gökalp, “Histopathologic changes in liver and renal tissues induced by different doses of diclofenac sodium in rats,” *Turkish J. Vet. Anim. Sci.*, vol. 27, no. 5, pp. 1131–1140, 2003.

[29] A. A. Abubakara, J. A. Maiyea, A. S. Yakubua, B. Saidub, U. Adamuc, and S. M. Sahabid, “Comparative effect of diclofenac sodium and dexamethasone on incisional wound healing in dogs,” *Sci J Vet Adv*, vol. 1, no. 4, pp. 94–100, 2012.

[30] Z. K. El-Maddawy and I. El-Ashmawy, “Hepato-renal and hematological effects of diclofenac sodium in rats,” *Glob. J. Pharmacol.*, vol. 7, no. 2, pp. 123–132, 2013.

[31] T. Jain *et al.*, “Diclofenac-induced biochemical and histopathological changes in white leghorn birds (*Gallus domesticus*),” *Indian J. Pharmacol.*, vol. 41, no. 5, p. 237, 2009.

[32] A. Y. Sharef, B. A. Hamdi, and Z. A. Alnajjar, “Histopathological aspects of co-administration of dexamethasone and diclofenac sodium on male albino rats,” *Zanco J. Med. Sci. (Zanco J Med Sci)*, vol. 24, no. 2, pp. 236–245, 2020.

[33] G. Marinova and V. Batchvarov, “Evaluation of the methods for determination of the free radical scavenging activity by DPPH,” *Bulg. J. Agric. Sci.*, vol. 17, no. 1, pp. 11–24, 2011.

[34] F. Albloui *et al.*, “Effect of hematocrit, galactose and ascorbic acid on the blood glucose readings of three point-of-care glucometers,” *Scand. J. Clin. Lab. Invest.*, pp. 1–8, 2022.

[35] V. Deved *et al.*, “Ascorbic acid for anemia management in hemodialysis patients: a systematic review and meta-analysis,” *Am. J. kidney Dis.*, vol. 54, no. 6, pp. 1089–1097, 2009.

[36] J. A. Colby *et al.*, “Effect of ascorbic acid on inflammatory markers after cardiothoracic surgery,” *Am. J. Heal. Pharm.*, vol. 68, no. 17, pp. 1632–1639, 2011.

[37] H. N. Mustafa, I. Alkan, Ö. G. Deniz, B. Z. Altunkaynak, E. Annaç, and S. Kaplan, “A Study on the Toxic Effect of Different Doses of Diclofenac Sodium on the Development of the Kidney in the Postnatal Period,” *Int. J.*

*Morphol.*, vol. 37, no. 3, 2019.

[38] F. Mor and O. Ozmen, “Effect of vitamin C in reducing the toxicity of endosulfan in liver in rabbits,” *Exp. Toxicol. Pathol.*, vol. 62, no. 1, pp. 75–80, 2010.

[39] K. Rehman *et al.*, “A biochemical and histopathologic study showing protection and treatment of gentamicin-induced nephrotoxicity in rabbits using vitamin C,” *African J. Tradit. Complement. Altern. Med.*, vol. 9, no. 3, pp. 360–365, 2012.