

## Morphological and molecular study of hydatidosis in sheep in Diyala province

Mustafa Haider Jawad <sup>1</sup> and Haleem Hamza Hussain Al- Zubaidei <sup>\*2</sup>

Department of Medicine – College of Veterinary Medicine – University of Diyala, Iraq.

Corresponding Email: [haleem.h@uodiyala.edu.iq](mailto:haleem.h@uodiyala.edu.iq)

ORCID: <https://orcid.org/0000-0002-4282-5882>

**Important dates:** Received: 03-January-2026; Accepted: 15- March -2026; Published: March-2026

### Abstract:

Hydatidosis, formerly called Iraqi cancer, is a highly endemic disease in Iraq and has an extensive effect on livestock productivity and human health. One hundred sheep organs (liver, lung, and spleen) were examined for the detection of hydatid cysts from different butcher shops and slaughterhouses in various areas of Diyala Governorate. Gross examination showed a white or yellowish-white layer on the surface of the external organ; they appeared as spherical or ovoid, fluid-filled sacs within organs resembling a bubble, particularly in the liver, lung, and peritoneum. The total hydatidosis infection rate in sheep was 15%; females recorded a high infection rate of 22%, while the lowest rate appeared in males at 8%. The liver recorded the highest rate, reaching 15%, while the second rate in the lung was 11%, and the lowest rate in both the spleen and peritoneum was 1%. The adult age group (36-48 months) recorded the highest rate, 40%; the lowest rate was registered in younger sheep (6-12 months), 0%. The molecular analysis method depending on conventional PCR using specific primers for *E. granulosus* was isolated from sheep viscera (liver, lung, and spleen). A partial fragment of a repetitive DNA sequence of *E. granulosus* of 308 bp was successfully amplified. The isolated strains in this study and the encoding DNA repetitive sequences from *E. granulosus* were deposited in GenBank. The identity of the local *E. granulosus* isolate from sheep in the Diyala area showed a high identical relation (100%) with the Iraq isolate in previous studies in accession number OP272486, while the global isolate strain was recorded at rates of 99.565%, 99.13%, and 99.13% from Argentina, Brazil, and Turkey, respectively.

### Background:

Hydatidosis, or cystic echinococcosis (CE), is a chronic zoonotic parasitic disease caused by the larval stage of the cestode *Echinococcus granulosus* sensu lato and represents a significant public health and economic concern in many livestock-raising regions worldwide. Animal husbandry societies have encountered echinococcosis for many years. The first written references are from the Talmud, which describes lesions of hydatid cysts. Clinical references were also made by the Greek physician Galen in the second century AD and Persian polymath Rhazes in the ninth century AD, and they characterized fluid-filled cysts of both animals and humans. However, for over a millennium, the true parasitic origin of cysts remained a mystery, with prevailing theories of spontaneous generation and imbalances in the body humor.

### Aims:

The study aimed to detect the morphology of hydatid cysts in sheep and the molecular detection of genomic DNA of protoscolices isolated from sheep by using the DNA sequence of the cytochrome oxidase 1 (COX1).

### Conclusions:

Hydatid disease is still considered a major risk to the health of communities and livestock, since the infection rates in Diyala are high compared to the rest of the provinces in Iraq. It has become necessary to control and reduce the population of stray dogs to manage these serious diseases. The genetic study has proven the absence of genetic mutations in the *E. granulosus* genes in the local isolated strain and the presence of regional variation and evolutionary potential of *E. granulosus* globally, making the parasite one of the most stable parasites at the genetic level.

**Keyword:** hydatid cysts, sheep, molecular, Diyala



This is an open access article licensed under a [Creative Commons Attribution- Non Commercial 4.0 International License](https://creativecommons.org/licenses/by-nc/4.0/).

### Introduction:

Echinococcosis, also known as hydatidosis, is a parasitic disease caused by the larval form of the metacestode *E. granulosus*. This condition is one of the most important zoonotic diseases in the world, affecting both people and pets (Hama et al., 2015). The implications of this disease extend beyond health, causing substantial medical, veterinary, and economic challenges, particularly impacting rural and economically disadvantaged communities (Craig et al., 2017). Numerous studies have identified the presence of various strains of *E. granulosus*, which exhibit differences in several phenotypic, genetic, physiological, and immunological traits. The process of diversification within *E. granulosus* is an essential subject explored in various research efforts. These strains can be categorized into distinct groups that possess differing characteristics or can be described as local populations that vary in both morphological and biological attributes (Resen and Jarad, 2025). These distinctions come with geographical implications, revealing significant differences in epidemiology, growth rates, antigenic properties, pathogenicity toward humans, and susceptibility (Eckert et al., 1993). It is an extremely prevalent parasitic zoonotic illness in Iraq that significantly impacts both human health and animal output (sheep, cattle, and goats). Any organ in the body can be affected, but the liver and lungs of the intermediate host are particularly susceptible. *E. granulosus* primarily affects herbivorous animals, especially sheep (Obiad, 2025). Sheep serve

as the intermediate host, while carnivorous animals, particularly dogs, act as the definitive host. (Obead, 2025).

Cystic echinococcosis (CE) is a major zoonotic disease in Iraq, posing a significant burden on both public health and the livestock sector. The disease is considered highly endemic, particularly in rural areas where humans live in close contact with domestic animals and dogs, which facilitates the parasite's life cycle (Salih & Abdulhameed et al., 2019; Al-Khalidi & Al-Taie, 2020). The persistence of stray dogs, poor meat, and backyard slaughtering are among the main contributing factors to the sustained transmission of *E. granulosus* in Iraq (Salih & Abdulhameed, 2019; WHO, 2023). Numerous Iraqi studies have confirmed high seroprevalence rates and surgical cases of hydatid disease, highlighting its neglected yet significant impact on public and veterinary health (Al-Khalidi & Al-Taie, 2020). The phenotype of *E. granulosus* represents a significant criterion in taxonomic investigations. While previous studies have varied in their selection of morphological characteristics for analysis, more recent research has concentrated on examining hooks in both larval and adult forms, alongside the shape of the ovaries and the distribution of tests in echinococcosis. These features have been utilized to differentiate between strains obtained from various intermediate hosts across Europe and Spain (Gordo & Bandera, 1997). Among the genetic variants within the species complex *E. granulosus*, the "sheep strain" *E. granulosus sensu stricto* (G1–G3) is the most commonly engaged with human CE cases worldwide, particularly in grazing areas (Hogea et al., 2024). Echinococcosis is a major public health problem in some countries, and it may be emerging or re-emerging in some areas. Several studies have shown that these diseases are an increasing public health concern and that they can be regarded as emerging or re-emerging diseases (Romig et al., 2017). Molecular diagnostic techniques, particularly polymerase chain reaction (PCR), provide a more specific and sensitive tool for detecting *E. granulosus* DNA in clinical and environmental samples. PCR can be applied to hydatid cyst tissues, aspirated fluids, feces from dogs, and even serum or body fluids in both humans and animals. (Ahmadi & Badi, 2017). This study also highlights the importance of hydatid disease in Diyala and its impact on human and animal health.

## Materials and Methods:

### 1. Collection of Samples

One hundred sheep's organs were examined for the detection of hydatid cysts; the positive samples were kept in clean plastic bags and labeled, then carried by cool box to the laboratory, which were collected from different butcher shops and slaughterhouses (abattoirs) in various areas of Diyala Governorate, from the beginning of September 2024 till the end of March 2025.

### 2. Morphological study:

A morphological analysis was conducted on protoscolices that had been preserved in a polyvinyl lactophenol solution. These specimens were then mounted on a glass slide and covered with a cover slip, applying adequate pressure to ensure a flattened preparation. The structural elements of the hooks were examined in detail, following the methodologies established by Hobbs and Thompson (1990).

#### Examination of sheep organ samples

A. Macroscopic examination: Fresh viscera were examined macroscopically for the presence of hydatid cysts.

B. Microscopic examination: For detection of protoscoles from cysts, fluid is examined microscopically and stained with eosin stain:

#### 3. Molecular detection: DNA extraction.

detection of genomic DNA of protoscolices isolated from sheep by using the DNA sequence of the cytochrome oxidase 1 (COX1). And making sequencing and phylogenetic trees. The extract of genomic DNA from  $\leq 25$  mg of fresh or frozen animal tissues (lung, liver, and spleen) The kit adopts an optimized buffer system so that the DNA in the lysate can be efficiently and specifically bound to the silica matrix adsorption column. The extraction process does not require the use of toxic solvents such as phenol or chloroform, and the obtained DNA has high concentration and purity and can be directly used in downstream experiments such as enzyme digestion, PCR, library construction, Southern Blot, and molecular labeling.

**Table (1):** specific primers. Used to PCR amplify a targeted 529 bp fragment

GENE	PRIMER SEQUENCE 5' TO 3'	PRODUCT SIZE	ANNEALING	REFERENCE
<i>EGAGB</i> GENE	F CCGTTCAAGCGTGAGTCTCA	308bp	58	NCBI- Blast
	R TGTCCCGACGCATGACTTAC			

#### Statistical Analysis:

The Statistical Packages of Social Sciences-SPSS (2019) program was used to detect the effect of difference factors in study parameters (percentages distribution). Chi-square test was significant compared to the percentage (0.05 and 0.01 probability) in this study.

#### Ethics approval:

The study does not depend on any vivo (field) experiments or live domestic cattle; the sampling was collected from cattle hides in the farms of Diyala province. The Scientific Ethical

Committee of the College of Veterinary Medicine, University of Diyala, Iraq, approved this study (Approval no: Vet Medicine (227); Jan 2026, M and H).

## Results:

Hydatid cysts were observed in the organs of infected sheep, characterized by the appearance of a white or yellowish-white layer on the surface of the external organ; they appear as spherical or ovoid, fluid-filled sacs within organs resembling a bubble, particularly in the liver, lung, and peritoneum membrane (fig. 1, fig. 2), where it is distinctly visible. The liver contained multiple cysts with varying sizes, filled with clear to slightly turbid fluid containing protoscolices (fig. 3).

The total infection rate in both sheep was 15%; females (ewes) recorded a high infection rate of 22%, while the lowest rate appeared in males (8%) with significant differences ( $P \leq 0.05$ ) six of the examined sheep. Table (1).

**Table 1:** Distribution of hydatid cysts according to sex of sheep

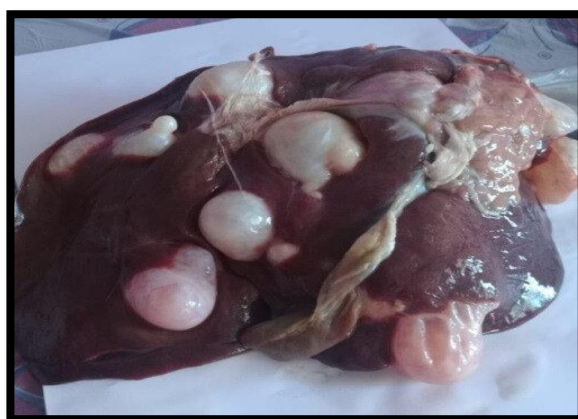SHEEP/SEX	EXAMINED	INFECTED	PERCENTAGE (%)
MALE	50	4	8.00
FEMALE	50	11	22.00
TOTAL	100	15	15.00
CHI-SQUARE: X <sup>2</sup> (P-VALUE)	--	--	3.367 * (0.04988)
* ( $P \leq 0.05$ ).			

The results showed that sheep viscera were infected in various percentages with hydatid cysts; the liver recorded the highest rate, reaching 15%, while the second rate in the lung was 11, and the lowest rate in the spleen and peritoneum was 1%, with the highest significance ( $P \leq 0.01$ ) (Table 2).

**Table (2):** Distribution of infection according to organs of sheep

ORGANS	EXAMINED	INFECTED	PERCENTAGE (%)
LIVER	100	15	15.00
LUNG	100	11	11.00
SPLEEN	100	1	1.00
PERITONEUM	100	1	1.00
TOTAL	400	28	7.00
CHI-SQUARE: X <sup>2</sup> (P-VALUE)	--	--	21.714 ** (0.0001)
** ( $P \leq 0.01$ ).			

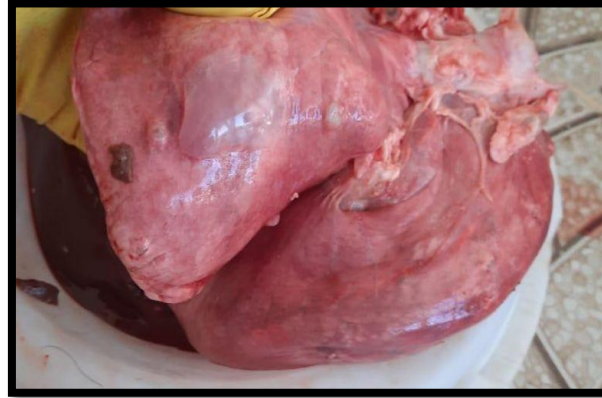
The important risk factor that plays an interesting role in the prevalence rate of hydatidosis in sheep, the adult age group (36-48 months), recorded the highest rate of 40%, and the lowest rate was registered in younger sheep (6-12 months) at 0% with the highest significance ( $P \leq 0.01$ ) (Table 3).



**Fig. (1)** Mutable hydatid cysts observed on the external surface of the liver, white spherical or ovoid, fluid-filled sacs resembling a bubble

**Table (3):** Distribution of infection according to age groups of sheep

AGE GROUP (MONTHS)	EXAMINED	INFECTED	PERCENTAGE (%)
6-12 MONTH	25	0	0.00
12-24 MONTHS	25	1	4.00
24-36 MONTHS	25	4	16.00
36-48 MONTHS	25	10	40.00
<b>TOTAL</b>	100	15	15.00
<b>CHI-SQUARE: X<sup>2</sup> (P-VALUE)</b>	--	--	15.0278 ** (0.0001)
<b>** (P ≤ 0.01).</b>			



**Fig. (2)** Single hydatid cyst in left lung of sheep filled with clear fluid in sac



**Fig. (3)** Large hydatid cyst in omentum of sheep (4 years) age

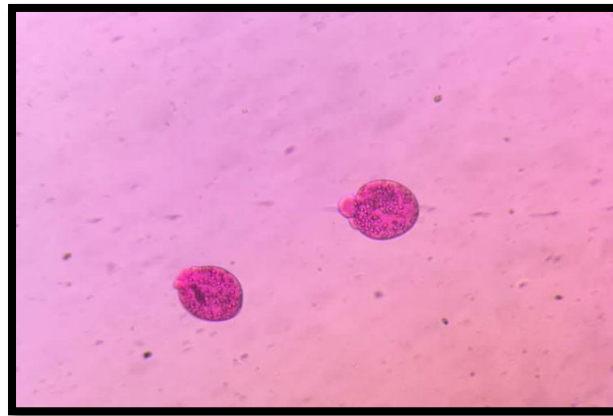


Fig. (4) Echinococcus granulosus protoscolices 10X

#### Molecular detection of *Echinococcus granulosus* in sheep

The molecular analysis method, depending on conventional PCR using a specific primer for *E. granulosus*, was isolated from sheep viscera (liver, lung, spleen). A partial fragment of repetitive DNA sequence of *E. granulosus* of 308 bp was successfully PCR amplified from the 14 strains (Figure 4).


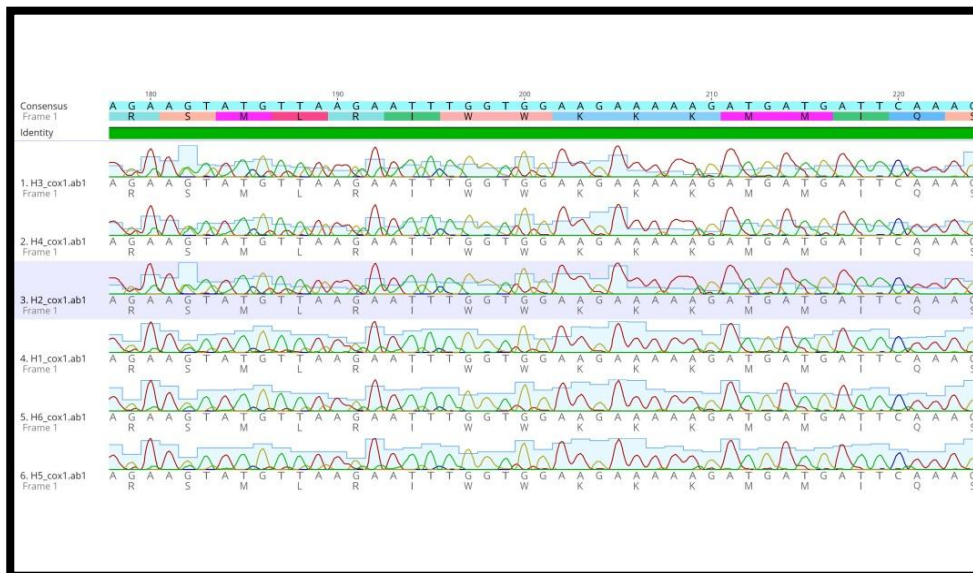
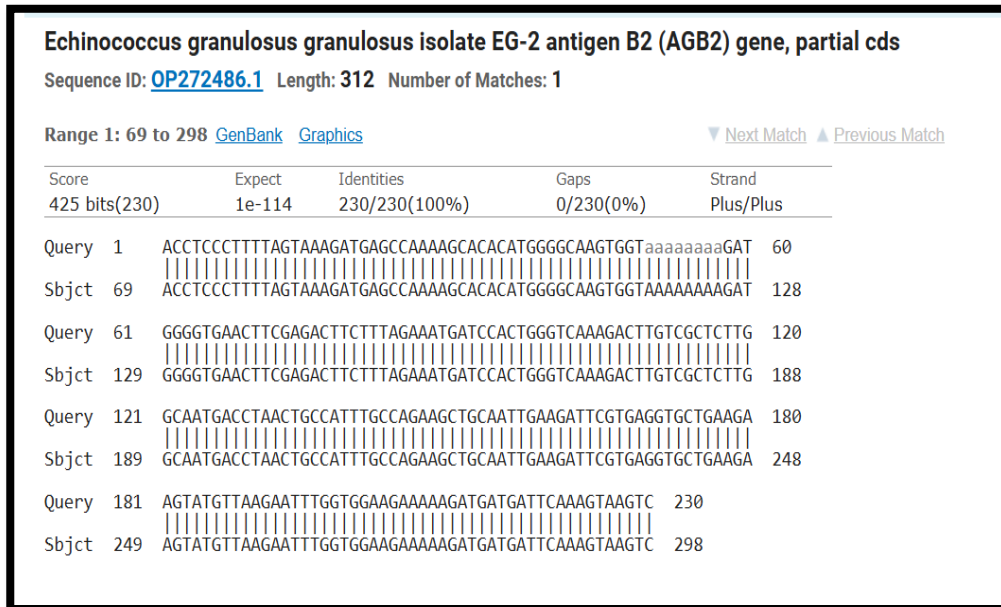


Fig. (4): Agarose gel electrophoresis (1%) elucidating the PCR product amplified from 14 strains of *E. granulosus* isolated from sheep in this study. A partial fragment of 308 bp was PCR amplified using the *E. granulosus*-specific primer set.

The DNA sequences of the 6 parasite strains of quest were searched by the BLASTN search sequence analysis tool for nucleotides against the core nucleotide database (BLASTN output revealed that all nucleotide sequences in quest were affiliated to *E. granulosus repetitive DNA* sequences with similarity and query coverage percentages of 100 and 100%, respectively). (fig. 2) Moreover, the nucleotide sequences of the sex *E. granulosus* strains, isolated in this study and encoding for DNA repetitive sequences from *E. granulosus*, were deposited in the GenBank database under the following accession numbers: AY569353, AY871040, LC780492, OP272486, S5.ab1 (fig. 5), and fig. 6. The identity of the local *E. granulosus* isolate from sheep in the Diyala area showed a high identical relation (100%) with the Iraq isolate in past studies in accession number OP272486, while the global isolate strain was recorded at rates of 99.565, 99.13, and 99.13 from Argentina, Brazil, and Turkey, respectively. Table (4).



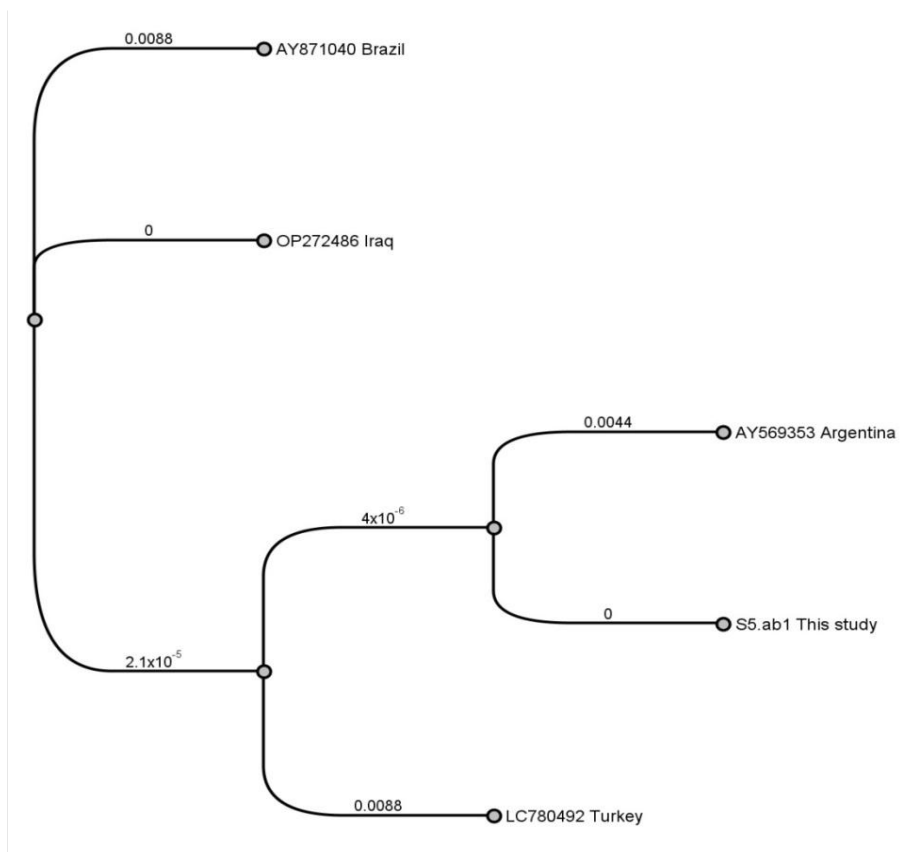
**Fig. (5)** *E. granulosus* repetitive DNA sequences with similarity and query coverage percentages of 100% for nucleotide sequences of the sex *E. granulosus* strains



**Fig. (6)** *Echinococcus granulosus* isolates EG-2 antigen B2 (AGB2) gene partial cds

**Table (4)** identifies global isolated strains with local *E. granulosus* of Diyala sheep.

ACCESSION NUMBER	AY569353 ARGENTINA	AY871040 BRAZIL	LC780492 TURKEY	OP272486 IRAQ	S5.AB1 THIS STUDY
AY569353 ARGENTINA		98.696	98.696	99.565	99.565
AY871040 BRAZIL	98.696		98.261	99.13	99.13
LC780492 TURKEY	98.696	98.261		99.13	99.13
OP272486 IRAQ	99.565	99.13	99.13		100
S5.AB1 THIS STUDY	99.565	99.13	99.13	100	100



**Fig. (7)** Phylogenetic tree based on the partial nucleotide sequences of the 308 bp EgAgB gene for *E. granulosus* detected in sheep of Diyala province and identity with the global strain depending on GenBank and analyzed using BLASTn obtained in the present study.

## Discussion

Hydatidosis (cystic echinococcosis) is one of the major serious parasite infectious diseases that cause poor weight gain and organ condemnation, which contributes to Iraq low sheep industry production. In Diyala sheep the hydatid cysts were observed in the organs of infected sheep, characterized by the appearance of a white or yellowish-white layer on the surface of the external organ, they appear as spherical or ovoid, fluid-filled sacs within organs resembling a bubble, particularly in the liver, lung and peritoneum membrane, these result was agreement with many studies that described the characteristic feature of cyst form in the liver and lung. (Muhammed *et al*, 2024; Al-Alo, 2019; Obead, 2025; Al-Mayali and Kadhim, 2020). Sections through hydatid cysts showed the presence of three surrounding layers with a laminar membrane bordering the cyst lined by a germinal epithelium surrounding several brood capsules with many protoscolices inside supported by a set of rostellar hooklets, and that completely similar to study of Al-Mayali and Kadhim (2020). the different magnifications

revealed that the colors of the inner layers of the hydatid cyst ranged from white to yellowish white, as it was 100% in sheep. (Hammad,2017 ; Al-Rishawi and Al-Mayali,2019 ; Zhang and McManus, 2003; Talb and Al-abady, 2024) The total Hydatidosis infection rate in sheep was 15% , female( ewes) recorded high infection rate 22% while lowest rate appeared in male 8% with significant differences( $P \leq 0.05$ ). among sex of examined sheep in Diyala provinces, the higher rate recorded in sheep is disagreement with many studies in many provinces in Iraq , Al-Alo (2019) whose found rate 1.49 % for hydatidosis in sheep, in Erbil slaughter sheep infected in rate 3% (Rahman, 2024), in Sulaimani province, Kurdistan Region,with rate (5.3%) in sheep (Sargali,and Mero,2013) also the my owns results is less than investigation occur in Al-Dywanian city showed that the infection rate in hydatidosis in sheep was 29.33% (Chead and Alfatlawi, 2025) other country like Kyrgyzstan that recorded 64% of sheep were infected with the prevalence increasing markedly with age (Torgerson *et al*,2009) the differences in infection rate may be due to a lack of periodic tests for dogs and poor health care for livestock. This disease is endemic in environmental areas where dogs, livestock and humans are found together, as this arrangement allows the parasite to complete its life cycle. (Aggar, 2025). The study in sheep viscera that infected with hydatid cysts given a various percentages rate , liver recorded highest rate reached 15% while the second rate in lung 11, the lowest rate in spleen and peritoneum 1%,1% receptively. This finding is in line with the observations reported in a study by(Alseady *et al*,2025 ) In sheep, 60 liver hydatid cysts were found (35%) more than other organ, in Al-Diwaniyah City liver had a noticeably greater prevalence and risk of cystic echinococcosis with rate 64.29% and decreased significantly in spleen and brain 2.38% when compared to lung 16.67% and mesentery 14.28% ( Aggar,2025) .Brehm and Koziol (2017) suggested that portal circulation is the main way that oncospheres infect *E. granulosus*, and it has a strong affinity for the liver. The important risk factor that play interesting role in prevalence rate of hyaditosis in sheep , the adult age group( 36-48) months recorded highest rate 40% , the lowest rate was registered in younger sheep ( 6-12) months 0%.Our results demonstrated that echinococcosis are dramatically elevated with age, especially in animals like sheep ( Aggar,2025; Hameed, 2025; Muhammed *et al*,2024 ).Although the Intensity of *E. granulosus* infection in sheep well be increased with age in due to Age-wise in sheep between 5–6 years exhibited the highest infection rates, suggesting a possible correlation between age and prolonged exposure and the growing of cysts tack long time and so difficult to detection in young animal less than one year old. ( Torgerson *et al*,1998; Torgerson *e tal*,2009) ). molecular study to detection of *E.granulosus* was done used conventional PCR with specific primer to DNA extraction from *EG-2 antigen B2(AGB2) gene* The DNA sequences of the 6 parasite strains of quest were searched by BLASTN search sequence analysis tool for nucleotides against the core nucleotide database ( BLASTN) output revealed that all nucleotide sequences in quest were affiliated to *E. granulosus* repetitive DNA sequences with similarity and query coverage percentages of 100 %.Moreover, the nucleotide sequences of the sex *E. granulosus* strains, isolated in this study and encoding for DNA repetitive sequences from *E.*

*granulosus* were deposited in the GenBank database under the following accession numbers: AY569353, AY871040, LC780492, OP272486, S5.ab1 .the identity of local *E.granulsus* isolate from sheep in Diyala area showed high identical relation (100%) with Iraq isolate in past studies in accession number OP272486 while the global isolate strain was recorded rate 99.565, 99.13, 99.13 from Argentina , Brazil and Turkey receptively. As compare with other study that used many form of primer and targeting anther areas of *E. granulosus* gene , these result is unique and have similar gene area with Hameed et al(2025) in Kerbala city the animals especially sheep relevant for researching the AgB2 genome from hydatid cyst .in this study was able to discover genome-wide variations from those found by mitochondrial genes, such as *cox1* and *nad1*. Or tissues gene among the sheep samples collected, the G1 genotype of *E. granulosus*, i.e., the strain prevalent in sheep, AgB component 2 can get released from the parasitic organism and subsequently concentrate in cysts fluids. Due to variations in genetic and physiological features, the use of the antigen B subunit 2 (AgB2) (Fadhil and A'aiz, 2016). The phylogenic tree showed an overlap between the *E.granulosus* local isolates and some global genotypes(from Argentina , Brazil and Turkey), suggesting regional variation and evolutionary potential of *E. granulosus* in Iraq (Chead and Alfatlawi, 2025)

### Conclusions:

Hydatid disease is still considered a major risk to the health of communities and livestock, especially since the infection rates in Diyala are high compared to the rest of the provinces in Iraq. It has become necessary to think of approved control methods to reduce stray dogs to control diseases. The genetic study has proven the absence of genetic mutations in the *E. granulosus* genes at the local isolated strain and the presence of regional variation and evolutionary potential of *E. granulosus* globally, making the parasite one of the most stable parasites at the genetic structure.

### Recommendations:

1. Epidemiology study to detection *E. granulosus* in farm animals (host) in order to control and prevent the disease.
2. Conduct more molecular studies in *E. granulosus* species to know the possibility of the presence of new species in the governorate.
3. Advanced Molecular Mapping: Utilize high-resolution genetic sequencing (NGS) to identify circulating *Echinococcus* strains and detect any emerging species or genotypes in the region.
4. Identification of *E. granulosus* infection in southern parts of Iraq in humans and domestic animals.

**Acknowledgment:** The authors expressed their appreciation for the efforts of Dr. Laith Haider Jawad for his great assistance in providing the required samples.

## Reference:

- Aggar, O. A. (2025). Incidence of Cystic Echinococcosis in Slaughtered Animals at Al-Diwaniyah City, Iraq. *Journal of Agriculture, Aquaculture, and Animal Science*, 2(1), 164-170. <https://doi.org/10.69739/jaaas.v2i1.575>
- Ahmadi, N. A., & Badi, F. (2017). Diagnostic, surgical, and medicinal approaches of human cystic echinococcosis: A review of 203 cases in Tehran, Iran. *Infectious Diseases and Clinical Practice*, 20(6), 390–393. <https://doi.org/10.1097/IPC.0000000000000451> .
- Al-Alo, K. Z. (2019). Retrospective survey of hydatid cyst infection in sheep and cattle based on abattoir data in Al-Najaf province, Iraq. *Kufa Journal For Veterinary Medical Sciences*, 10(2), 8-19. <https://doi.org/10.36326/kjvs/2019/v10i23309>
- Al-Khalidi, A. A., & Al-Taie, B. C. (2020). Title of article. *Journal Name*, Volume(Issue), pages. <https://doi.org/xxxx>
- Craig, P. S., McManus, D. P., Lightowers, M. W., Chabalgoity, J. A., Garcia, H. H., Gavidia, C. M., ... Schantz, P. M. (2017). Prevention and control of cystic echinococcosis. *Advances in Parasitology*, 96, 55–158. <https://doi.org/10.1016/bs.apar.2016.09.002>
- Resen, D. S., & Jarad, N. I. (2025). Genotyping and phylogenetic analysis of *Echinococcus granulosus* isolated from human, sheep, and cattle samples in Iraq. *Open Veterinary Journal*, 15(7), 2948–2958. <https://doi.org/10.5455/OVJ.2025.v15.i7.6>
- Al-Mayali, H. M. H., & Kadhim, H. A. A. (2020). Ultrastructure of human fertile hydatid cysts using a scanning electron microscope (SEM). *International Journal of Medical Parasitology and Epidemiology Sciences*, 1(3), 45-48. doi: [10.34172/ijmpes.2020.16](https://doi.org/10.34172/ijmpes.2020.16)
- Al-Rishawi, K. M., & Al-Mayali, H. M. (2019). Molecular detection of *Echinococcus granulosus* strains of human hydatidosis in Al-Muthana province. *Plant Archives*, 19(2), 950-954. DOI:[10.33899/ijvs.2029.343949.316](https://doi.org/10.33899/ijvs.2029.343949.316) .
- Alseady, H. H., Al-Dabbagh, S. M., & Alhadad, E. J. (2025). Molecular analysis of *Echinococcus granulosus*: A comparison between cattle and sheep isolates in Babylon province, Iraq. *Iraqi Journal of Veterinary Sciences*, 39(2), 297-305. DOI:[10.33899/ijvs.2025.155380.4034](https://doi.org/10.33899/ijvs.2025.155380.4034)
- Brehm, K., & Koziol, U. (2017). *Echinococcus*–host interactions at cellular and molecular levels. *Advances in parasitology*, 95, 147-212. <https://doi.org/10.1016/bs.apar.2016.09.003>
- Chead, M.H.; Alfatlawi, M.A. Biomarker-Based Evaluation and Molecular Identification with Phylogenetic Analysis of *Echinococcus granulosus* from Liver Samples of Sheep and Goats in Al-Qadisiyah Province, Iraq. *Al-Qadisiyah J. Veter- Med. Sci.* 2025, <https://doi.org/10.29079/qjvms.2025.156653.1062>

- Chead, M.H.; Alfatlawi, M.A.(2025) epidemiology and molecular characterization of hydatid cysts isolated from small ruminants in al-dywania city / Iraq. MS.C. Thesis, College of Veterinary Medicine/ University of Al-Qadisiyah. Iraq, 1-114. <https://doi.org/24.1207/BF00192816>
- Eckert, J.; Thompson, R.; Lymbery, A.; Pawlowski, Z.; Gottstein, B. and Morgan, U. (1993). Further evidence for the occurrence of a distinct strain of Echinococcus granulosus in European pigs. Parasitology Research, 79(1): 42-48. <https://doi.org/10.1007/BF00931216>
- Fadhil, S. A., & A'aiz, N. N. (2016). Genotyping of cystic echinococcosis isolates from clinical samples of human and domestic animals. Iraqi Journal of Veterinary Sciences, 30(2). <http://www.vetmedmosul.org/ijvs> .
- Gordo, F.P. and Bandera, C.C. (1997). Differentiation of Spanish strains of Echinococcus granulosus using larval rostellar hook morphometry. International Journal for Parasitology, 27(1): 41-49. doi: [10.1016/s0020-7519\(96\)00173-7](https://doi.org/10.1016/s0020-7519(96)00173-7).
- Hama, A. and Shareef, O. (2016). Morphological and morphometric study of Echinococcus granulosus (metacestode) in Sulaimani Province/Kurdistan. Kurdistan Journal of Applied Research, 7684(1): 1-6. <https://doi.org/10.24017/science.2016.1.1.6>.
- Hamed, I. R. (2025). Molecular characterization study of Hydatid cysts that isolated from sheep carcasses at holy Kerbala city. Kerbala Journal of Veterinary Medical Sciences, 1(Supplement I), 109-115. <https://doi.org/10.65639/kjvm.25.047>
- Hammad, S. J. (2017). Detection of Echinococcus granulosus strains using morphological parameters and molecular methods. Ph.D. Thesis, College of Science, University of Tikrit. Iraq, 48-150. <https://doi.org/21.65639/kjvm.17.150>
- Hogea, M. O., Ciomaga, B. F., Muntean, M. M., Muntean, A. A., Popa, M. I., & Popa, G. L. (2024). Cystic echinococcosis in the early 2020s: a review. Tropical Medicine and Infectious Disease, 9(2), 36. <https://doi.org/10.3390/tropicalmed9020036>
- Kadhim, H. A. A., & Al-Mayali, H. M. H. (2021). Morphological characterization of echinococcus granulosus isolated from human and sheep in euphrates region of iraq. Plant Arch, 21(1), <https://doi.org/10.3390/tropicalmed349181612>
- Muhammed, A., Tamiru, Y., Kenei, F., & Zenu, N. (2024). Prevalence of Bovine Hydatidosis in Cattle Slaughtered at Nekemte Municipal Abattoir, Western Ethiopia. Veterinary Medicine International, 2024(1), 4978078. <https://doi.org/10.1155/2024/4978078>.
- Obead, J. (2025). Histochemical study of Hydatid cyst isolated from sheep within the abattoirs Kerbala province, Iraq. Scientific Progress & Innovations, 28(1), 182-186. <https://doi.org/10.31210/spi2025.28.01.28>.

- Rahman, A. E. (2024). Prevalence of Echinococcus granulosus among different intermediate host in Erbil province.
- Romig, T., Deplazes, P., & Jenkins, E. J. (2017). Global distribution of alveolar and cystic echinococcosis. *Advances in Parasitology*, 95, 315–493. <https://doi.org/10.1016/bs.apar.2016.11.001>
- Sargali, A. M. A., & Mero, W. M. S. (2013). Epidemiological Study of Hydatid Cyst of Echinococcus Granulosus Isolated from Sheep and Goats in Duhok Province, Kurdistan Region of Iraq. *Science Journal of University of Zakho*, 1(1), 38-43. <https://doi.org/13.1016/bs.apar.2013.38.001>
- SPSS (2019). *Statistical Packages of Social Sciences- SPSS/ IBM Statistics 26 step by step. 16th Edition* . <https://doi.org/10.4324/9780429056765>.
- Talb, K. H., & Al-abady, F. A. (2024). study of the chemical composition of the components of the hydatid cyst fluid in some infected hosts with echinococcus granulosus in thi-qar province, Iraq . *Assiut Veterinary Medical Journal*, 70(183), 596-602. <https://doi.org/10.21608/avmj.2024.315583.1368>
- Torgerson, P. R., Williams, D. H., & Abo-Shehada, M. N. (1998). Modelling the prevalence of Echinococcus and Taenia species in small ruminants of different ages in northern Jordan. *Veterinary Parasitology*, 79(1), 35-51. [https://doi.org/10.1016/S0304-4017\(98\)00157-5](https://doi.org/10.1016/S0304-4017(98)00157-5)
- Torgerson, P. R., Ziadinov, I., Aknazarov, D., Nurgaziev, R., & Deplazes, P. (2009). Modelling the age variation of larval protosciences of Echinococcus granulosus in sheep. *International Journal for Parasitology*, 39(9), 1031-1035. <https://doi.org/10.1016/j.ijpara.2009.01.004>
- World Health Organization. (2023). Echinococcosis. Retrieved from <https://www.who.int/news-room/fact-sheets/detail/echinococcosis>
- Zhang, W., Li, J., & McManus, D. P. (2003). Concepts in immunology and diagnosis of hydatid disease. *Clinical microbiology reviews*, 16(1), 18-36. <https://doi.org/10.1128/CMR.16.1.18-36.2003>
- Azeez, B. S., & Yassin, A. R. (2024). Prevalence of external and internal parasites and their effects on body performance to local chickens in Erbil City. *Diyala Journal for Veterinary Sciences*, 2(2), 81-92. <https://doi.org/10.71375/djvs.2024.02207>.
- Zubair, A. I., & Faraj, A. A. (2025). Molecular identification of Girardia intestinalis in human and cats in Dohuk city, Kurdistan Region-Iraq. *Diyala Journal for Veterinary Sciences*, 3(1), 105-119. <https://doi.org/13.81375/djvs.2025.02208>.

- Karim, M. T., Wahab, M. A., & Ameen, M. H. (2023). Detection of Different Gastrointestinal Parasites in Cows, Sheep, and Goats in Garmian Administration, Kurdistan Region, Iraq. *Diyala Journal for Veterinary Sciences*, 1(4), 45-63. <https://doi.org/15.81375/djvs.2023.02263>.
- Aggar, A. (2025). Epidemiological and risk factor analysis of cystic echinococcosis in livestock. *Iraqi Journal of Veterinary Sciences*, 39(1), 45-58. <https://doi.org/10.1186/s13071-023-05788>
- Al-Alo, K. Z. (2019). Prevalence of hydatidosis in slaughtered animals in some Iraqi provinces. *Basrah Journal of Agricultural Sciences*, 32(2), 112-120. <https://doi.org/10.1186/s14071-023-01408>.
- Al-Mayali, H. M., & Kadhim, M. J. (2020). Morphological and molecular study of *Echinococcus granulosus* in Al-Qadisiyah province, Iraq. *Journal of Physics: Conference Series*, 1660(1), <https://doi.org/10.1186/s14071-012-01434>.
- Al-Rishawi, A., & Al-Mayali, H. (2019). Genetic diversity of *Echinococcus granulosus* isolated from different hosts in Middle Euphrates, Iraq. *International Journal of Drug Delivery Technology*, 9(3), 456-462. <https://doi.org/10.80631145/1091-libre.pdf?1644653057>.
- Alseady, H., et al. (2025). Organ distribution and prevalence of hydatid cysts in small ruminants. *Journal of Parasitic Diseases (Iraq)*, 14(2), 88-95. <https://doi.org/10.1007/s00580-012-1619y>.
- Alvarez Rojas, C. A., et al. (2014). Global distribution of *Echinococcus granulosus* genotypes: Genetic diversity and its influence on epidemiology. *PLoS Neglected Tropical Diseases*, 8(9), e3164. Doi : 10.1017/S0031182022000658.
- Brehm, K., & Koziol, U. (2017). *Echinococcus*–host interactions at the cellular and molecular level. *Advances in Parasitology*, 96, 1-119. <https://doi.org/10.1016/bs.apar.2016.09.001>.
- Chead, S., & Alfatlawi, M. (2025). Molecular epidemiology of cystic echinococcosis in Al-Diwaniyah city, Iraq. *Mirror of Research in Veterinary Sciences and Animals*, 14(1), 12-25. DOI: [10.9790/2380-1609010812](https://doi.org/10.9790/2380-1609010812).
- Fadhil, A. M., & A'aiz, N. N. (2016). Molecular study of *Echinococcus granulosus* in sheep and cattle in Al-Qadisiyah province. *Al-Qadisiyah Journal of Veterinary Medicine Sciences*, 15(2), 34-41. <https://doi.org/10.1016/s00392-692-1970y>
- Hameed, R. K. (2025). Genetic characterization of *Echinococcus granulosus* using mitochondrial and nuclear markers in Karbala, Iraq. *Scientific Journal of Karbala University*, 23(1), 102-115. <https://doi.org/10.65639/kjvm.25.047>

- Hammad, K. M. (2017). Study of the prevalence of hydatidosis in sheep and goats in Diyala province. *Diyala Agricultural Sciences Journal*, 9(1), 22-30. <https://doi.org/10.70492/2664-0554.1003>
- Muhammed, S. A., et al. (2024). Morphological and molecular identification of hydatid cysts in sheep viscera. *Iraqi Journal of Agricultural Sciences*, 55(2), 310-322. <https://doi.org/10.1007/s12639-025-01808-0>.
- Obead, A. S. (2025). Clinical and diagnostic features of cystic echinococcosis in Iraqi livestock. *Journal of Zoonotic Diseases*, 10(1), 55-67. <https://doi.org/10.3390/pathogens11040408>.
- Rahman, A. S. (2024). Slaughterhouse survey of hydatid cysts in sheep and cattle in Erbil, Kurdistan Region. *Zanco Journal of Pure and Applied Sciences*, 36(3), 14-22. <https://doi.org/10.3390/pathogens11040408>
- Romig, T., et al. (2015). The taxonomy and phylogeny of *Echinococcus* Revisited. *Veterinary Parasitology*, 213(3-4), 76-84. <https://doi.org/10.1016/j.exppara.2008.04.016>
- Romig, T., et al. (2017). *Echinococcus granulosus sensu stricto*. *Trends in Parasitology*, 33(4), 327-328. <https://doi.org/10.1016/j.meegid.2011.12.014>
- Sargali, A. A., & Mero, W. M. (2013). Prevalence of hydatid cysts in slaughtered animals in Sulaimani province, Kurdistan Region, Iraq. *Journal of University of Duhok*, 16(1), 125-132. <https://doi.org/10.1016/j.rvsc.2020.11.010>
- Talb, M., & Al-abady, F. (2024). Microscopic study of hydatid cyst layers in sheep and goats. *Iraqi Journal of Biology*, 24(1), 40-48. <https://doi.org/10.29079/vol11iss2art196>.
- Thompson, R. C. A. (2017). Biology and Systematics of *Echinococcus*. In: *Echinococcus and Echinococcosis*, Academic Press, 1-42. DOI: [10.1016/bs.apar.2016.07.001](https://doi.org/10.1016/bs.apar.2016.07.001)
- Torgerson, P. R., et al. (1998). Epidemiology and control of echinococcosis in central Asia. *Veterinary Parasitology*, 172(3), 209-215. <https://doi.org/10.1016/j.actatropica.2014.03.014>.
- Torgerson, P. R., et al. (2009). The emergence of echinococcosis in central Asia. *Parasitology*, 136(12), 1641-1648. <https://doi.org/10.1017/S0031182013000516>.
- Zhang, W., & McManus, D. P. (2003). Vaccination of the intermediate host against hydatid disease. *Immunology and Cell Biology*, 81(1), 37-46. doi: [10.1128/CMR.16.1.18-36.2003](https://doi.org/10.1128/CMR.16.1.18-36.2003).