

## Saffron Extract Ointment for Treatment of Open Wounds

Mohammed Ali Mohammed and Assist. Prof. Muslem F. diwan

The Department of Surgery and Obstetrics College of Veterinary Medicine, University of Al-Qadisiyah in Iraq.

**Corresponding Author: E.mail: [Muslem.diwan@qu.edu.iq](mailto:Muslem.diwan@qu.edu.iq)**

### Abstract:

This study compared the saffron extract group to the control group for wound therapy in rats. Twenty male white rats were housed in plastic cages, with containers randomly assigned to two groups of ten rats. All rats underwent conventional surgery under general anesthesia, resulting in surgical incision injuries on the dorsal region of their backs. A 2 cm long wound was made using a surgical blade and ruler. Increased blood flow, edema, fibrous tissue, and crust formation were observed during examination. Treatments were applied to the wound surface once daily for seven days. Biopsies were taken on the seventh, fourteenth, and twenty-first days to assess healing, with morphological observations reported on each of these days. The best outcomes were observed in G2. On the final wound healing examination, G2 showed significantly more wound contraction than G1. The evaluation indicated that G2 outperformed G1 in wound assessment, supported by additional criteria. Histological changes after saffron treatment revealed complete recovery of all skin layers, including the epidermis, dermis, and underlying tissue. In contrast, G1 (control) showed a regenerated epidermal stratum, interstitial spaces between the outer skin and underlying layers, swelling or vesicular lesions within these layers, and swelling beneath the skin, with inflammatory cells, primarily lymphocytes, present in the dermal layer.

**Keywords:** *Saffron, Open wounds, Healing*

**DOI:** 10.71375/djvs.2025.03102

## Introduction

Despite being the biggest organ in the body, the skin only makes about 15% of an adult human's total body weight (Kolarsick et al., 2011). In addition to preventing excessive water loss from the body and playing a part in thermoregulation, it also protects the body from external physical, chemical, and biological threats. The mucous membranes that line the body's surface is part of the continuous skin (Bergfelt, 2008).

Wounds are one of the biggest health problems in the world, and infections are one of the most common and serious complications for wound patients with wounds (Mahmood Ahmed, 2023).

Following damage to the skin or underlying tissues/organs due to surgery, blows, cuts, chemicals, heat or cold, friction, shear force, pressure, or disease, such as leg ulcers or Tumor, a wound is a breakdown of the skin, the loss of continuity of epithelium, with or without loss of underlying connective tissue (Gupta, 2021; Wilkins and Unverdorben, 2013). An inflammatory reaction to the physical rupture of tissue initiates the multi-layered process of wound healing, which is composed of successive but overlapping phases (Johnson et al., 2018). In reality, inflammatory cells and

mediators interact intricately and precisely to promote wound

healing, creating a substantial overlap between the stages of wound healing. The proliferative phase (angiogenesis, granulation, reepithelialization), the remodeling phase (extracellular matrix (ECM) remodeling), and the inflammatory phase comprise the three main stages of cutaneous wound healing. Hemostasis (emphasizing the significance of vascular responses), inflammation, proliferation, and tissue remodeling or resolution are the four stages of wound healing that some authors have separated (Öztürk & Ermertcan, 2011). Throughout history, saffron has been used for a variety of therapeutic purposes, in Persian traditional medicine. Various mechanisms for saffron's wound-healing action have been proposed by earlier research. The increase in TGF- $\beta$ 1 levels in the wound bed of rats treated with saffron is said to stimulate the migration and proliferation of fibroblasts. It is also hypothesized that increased hydroxyproline and dry matter content in the saffron-treated wounds are the cause of improved epitheliogenesis and wound healing. Additionally, saffron and its constituents shown antioxidant and anti-inflammatory properties that enhance the

healing process of wounds (Deldar et al., 2021) . From the Late Bronze Age onwards, saffron (*Crocus sativus* Linnaeus) has been used medicinally throughout Asian nations, Its ability to reduce the risk of a number of diseases has been confirmed by recent research, Due to their hypolipidemic, antitussive, antioxidant, and antidiabetic properties, among many others, some metabolites obtained from saffron stigmas provide a wide range of medicinal benefits, *Crocus sativus* L, water and ethanol saffron extracts have cardioprotective properties and prevent neurodegenerative diseases, Numerous saffron components, including crocetin and crocins, have potent antioxidant and radical scavenger qualities that protect against a range of pro-inflammatory cytokines and radical oxygen species, which accounts for many of the plant's therapeutic benefits (Poma et al., 2012).

### **Ethical Approval**

The study was conducted in accordance with ethical guidelines for animal research, and the experimental protocol was approved by the Scientific Committee of the College of Veterinary Medicine in the University of Al- Qadisiyah, Iraq. All efforts were made to minimize animal suffering and ensure humane handling throughout the experiment.

### **Materials and Methods**

Iran was the source of the saffron. were processed for 20 minutes into fine particles in a dry grinder. A 212-micron mesh size was used to sieve the powder. For a 24-hour ethanolic saffron extraction using a Soxhlet apparatus, 50 grams of saffron powder are placed in an extraction thimble at 60 degrees Celsius. To make the saffron powdered extract, the ethanolic extract is scraped and processed after being placed in Petri dishes until the alcohol evaporates at 50 degrees Celsius (Alara et al., 2018) .

### **Saffron extract ointment preparation**

The dry saffron extract was carefully ground to particles smaller than 75µm in order to create fine, homogenized extract powder particles. A fine powder was produced using sieve No. 200 ,Using a glass mortar and pestle, the Vaseline and saffron extract were crushed to make the ointment (Chhetri et al., 2010; Sharma & Singh, 2014).A 5% saffron extract ointment was made by mixing 5 grams of saffron extract powder with 95 grams of Vaseline. A small amount of pure liquid glycerin was put to the mortar first, and the powder was then added and thoroughly crushed with a pestle to dissolve the contents. After adding a tiny bit of Vaseline, the mixture was triturated using a pestle. After that, more Vaseline was added gradually, and the mixture was once again triturated until all 95 grams of Vaseline had

been used and it was uniform, the mixture was put into a container and vigorously mixed by continually inverting it with a vortex mixer for ten minutes in order to increase the homogeneity of the mixture. After that, the prepared ointment was put in a dark container and kept at room temperature until it was needed (L.M. Jabbar and T.A. Abid, 2024).

### Experimental design

this study depended used twenty (20) mature rats. On the animal's back, opening, full-thickness skin incision measuring 2 cm in longitudinal was performed. Ten animals were split into two groups randomly. G1 (control group) is not given any treatment. For seven days in a row, the wounds of the G2 (saffron extract group) were treated topically with 5% saffron extract ointment at a dose of 30 mg/cm<sup>2</sup> used daily. Direct measurements of wound dimensions on days 7, 14, and 21 PI were depended to conduct a morphometric analysis of wound healing. After 7-, 14-, and 21-days post-infection, specimens of healed skin (1 cm<sup>3</sup>) were obtained for histological analysis of the healing process.

### Statistical Analysis

The significance between groups was determined using statistical analysis of the morphometric data. The data were subjected to one-way analysis of variance

(ANOVA) to assess the overall differences between the groups at each time point (7, 14, and 21 days). To determine which specific groups differed, post-hoc comparisons were made using the Least Significant Difference (LSD) test. A p-value of  $\leq 0.05$  was considered statistically significant (Ghaith & Eman, 2024).

## Results

### Morphometric assessment of the wound healing:

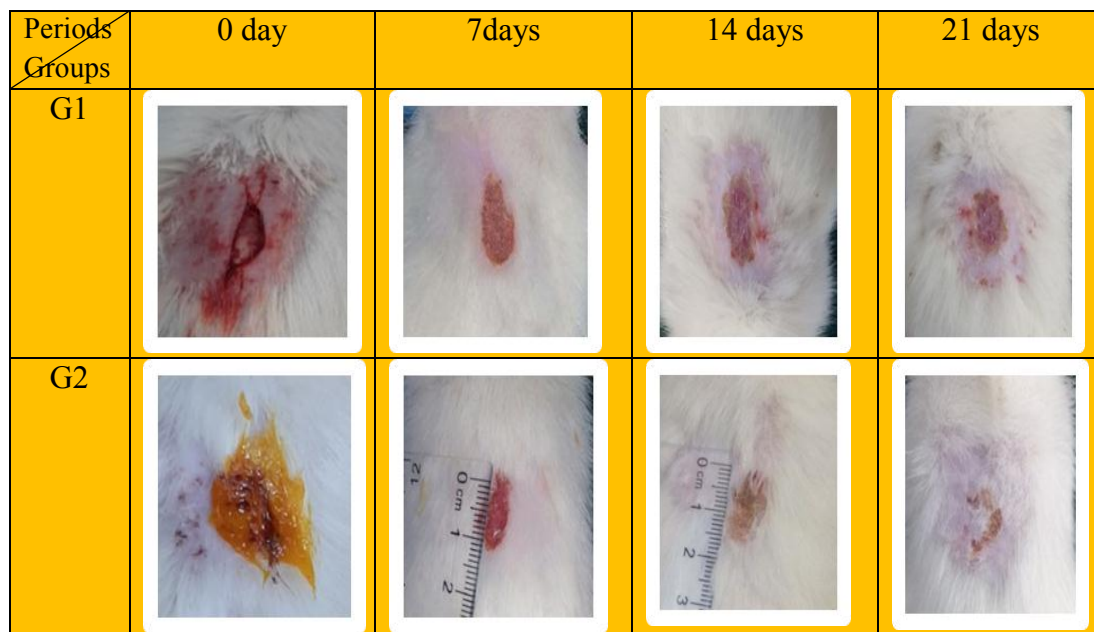
#### Surface area (size of wound)

On day zero, the initial wound size (mm<sup>2</sup>) for both treated and control wounds was 93.1 mm. The size of the untreated wounds in G1 was 60.38 mm at the 7th day PI, whereas the treated wounds in G2 were considerably ( $P < 0.05$ ) less than the initial wound size, at 52.40. The size of untreated wounds in G1 was 43.007 at the 14th day PI, with no healing, whereas in G2, the size decrease was considerably smaller (28.06). Compared to wound contraction (%) in G1, the percentage of wound contraction was significantly higher ( $P < 0.05$ ) in treated wounds at 7 and 14 days.

**Table (1):** Surface area and wound contraction. (G1=Control), (G2= saffron group).

Groups Periods	Surface area (mm <sup>2</sup> )			
	0 day	7 days	14 days	21 days
G1	93.1 ± 0 Aa	60.38 ± 0.878 Ab	43.007 ± 0.735 Ac	29.68 ± 0.785Ad
G2	93.1 ± 0 Aa	52.40 ± 0.928 Cb	28.06 ± 0.651 Cc	10.46 ± 0.450 Cd
Groups Periods	wound contraction			
	0 day	7 days	14 days	21 days
G1	0 ± 0 Aa	35.14 ± 0.94 Ab	28.78 ± 0.46 Ac	31.06 ± 0.79 Ac
G2	0 ± 0 Aa	43.7 ± 0.99 Bb	46.47 ± 0.51 cc	62.78 ± 1.03 Bd
2.70<LSD (P0.05)				

- Capital letters indicate vertical statistical comparisons, while small letters denote horizontal statistical comparisons.
- Different letters indicate a significant difference (P<0.05), while comparable letters indicate no meaningful difference.



**Figure :** Morphology Initially, a 2 cm longitudinal incision was made on the backs of the rats (oval shape)

### Histopathological assessment of the wound healing

#### On 7th day post wound injury

**W1-G1.** Histopathological changes following wound injury after one week showed the presence thick crust attached

closely with the edges of wound and profuse purulent exudate and wide scar tissue with profuse granulation tissue in the dermis (Fig. 2). profuse purulent exudate which formed from dead neutrophils and tissue debris and thick crust above the



edges of wound. Thin and branched network of collagen fibers in the dermis (Fig 3)

**W1-G2.** Histopathological changes following wound injury after one week showed Wide scar tissue with profuse granulation tissue in the dermis. Thick crust with purulent exudate above the epidermis. few hyperplasia of stratum basale above the edges of wound. Few amounts of collagen also present in the dermis (Fig4).

#### **On 14th day post wound injury**

**W2-G1.** Histopathological changes following wound injury after second week showed complete sloughing of epidermal layers with slightly hyperplasia on both edges of the wound. Profuse granulation tissue with wide scar tissue (Fig5). Few hyperplasia on the edge of the wound with profuse granulation tissue which contain high fibrosis and newly formed, small blood vessels (Fig. 6).

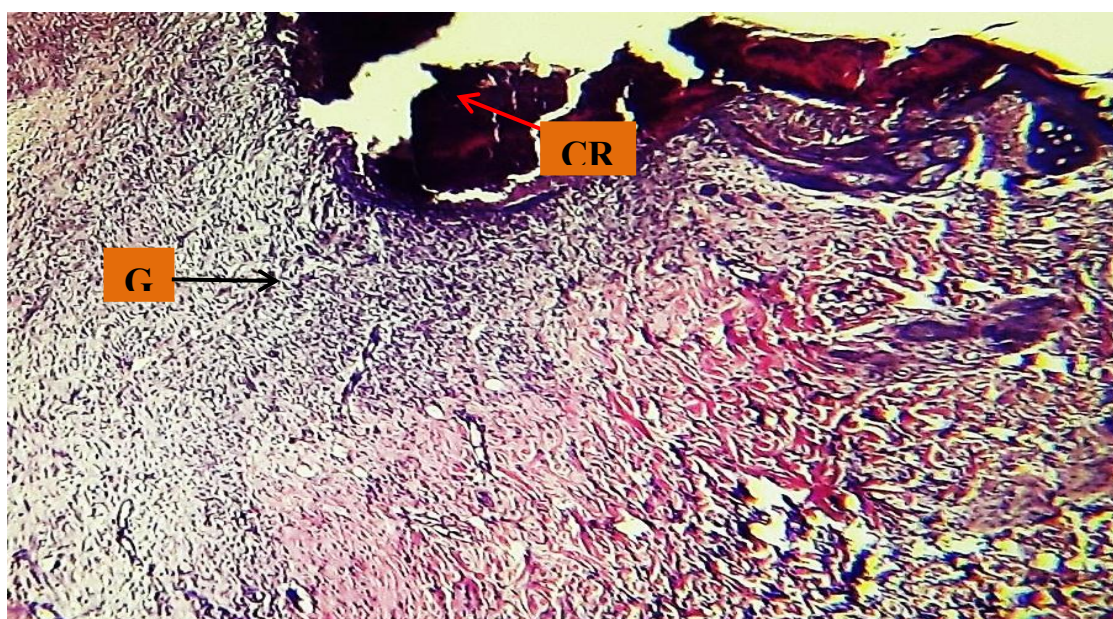
**W2-G2.** Histopathological changes following wound injury after second week showed thick cracked crust above the epidermal layers with few proliferations of stratum basal. Profuse granulation tissue and moderate amount of thin branched collagen network in the dermis (Fig. 7).

hyperplasia of stratum basal with thick crust above it. Profuse granulation tissue characterized by new formation of small blood vessels with fibrosis and branched network of collagen in the dermis (Fig. 8).

#### **On 21st day post wound injury**

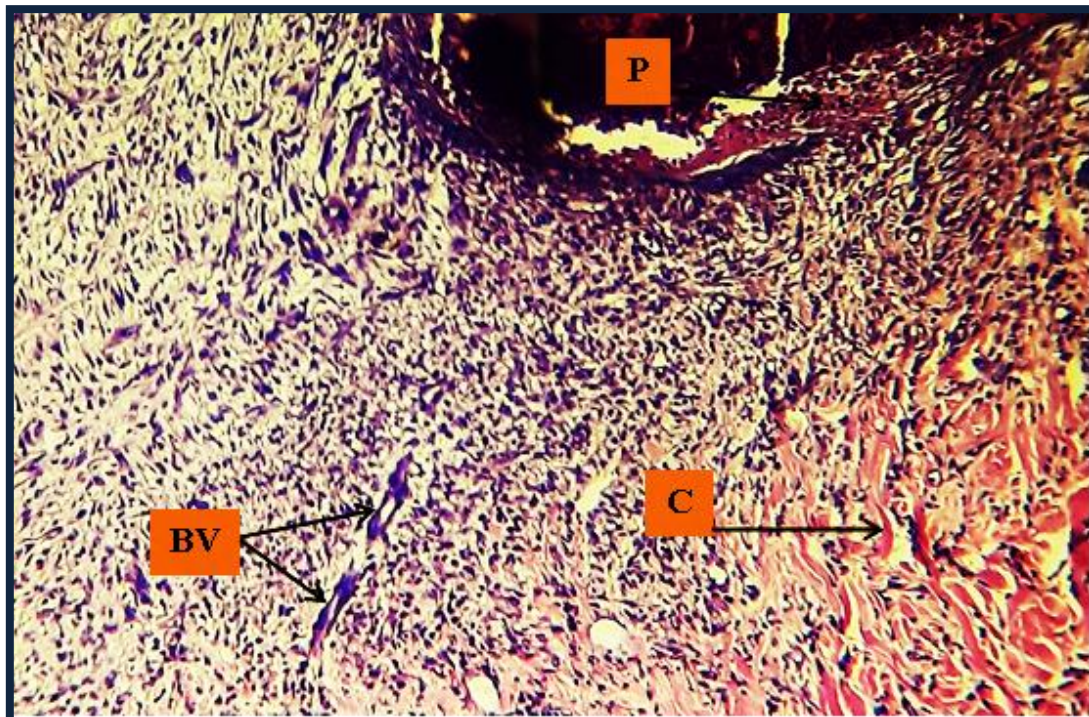
**W3-G1.** Histopathological changes following wound injury after third week showed Thin and proliferating epidermal layers above the edges of the wound. wide scar tissue in the dermis with profuse fibrosis horizontally on the wound of the edges and small, newly formed blood vessels vertically on it (Fig. 9). New and few hyperplasia of stratum basal with thin keratinized layer above it. In the dermis, there is scattered infiltration of macrophages with profuse fibrosis and few blood vessels formation (Fig. 10).

**W3-G2.** Histopathological changes following wound injury after third week showed thin keratinized layer and thick epidermal layers. Wide scar tissue in the dermis with profuse fibrosis and newly formed small blood vessels (Fig. 11). Marked thin keratinized layer with proliferating epidermal layers. In the dermis there is newly-formed small blood vessels with fibrosis (Fig. 12).

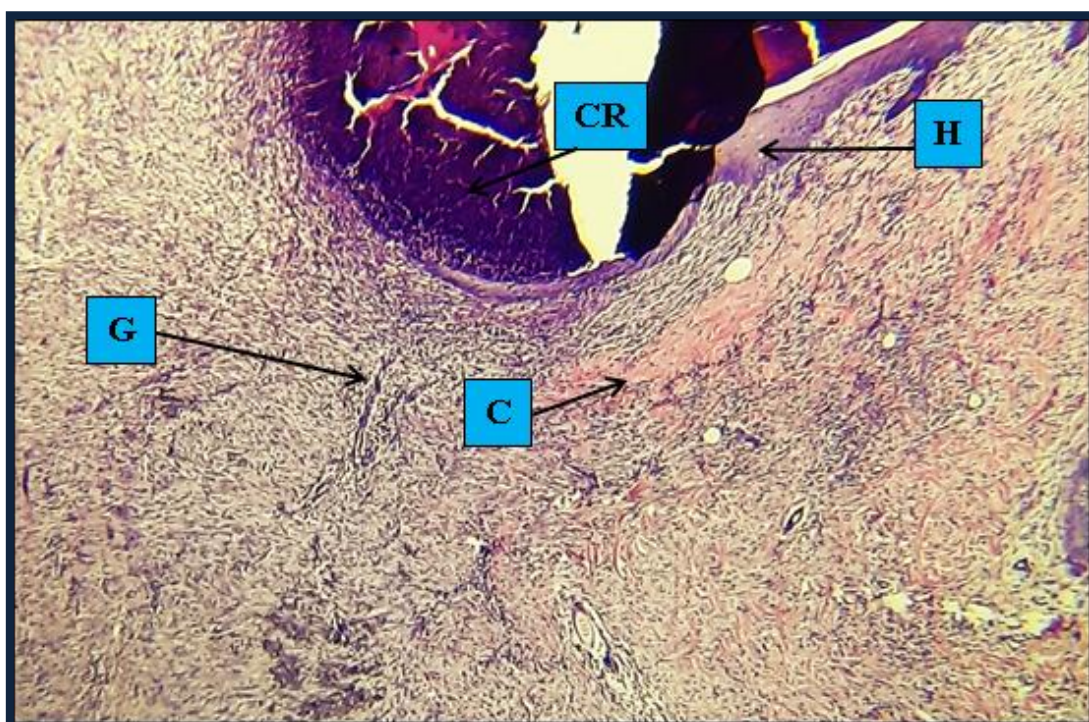




**Figure G1:** Thick crust (CR) attached closely with the edges of wound and profuse purulent exudate and wide scar tissue with profuse granulation tissue (G) with newly formed blood vessels in the dermis. 4X H&E.

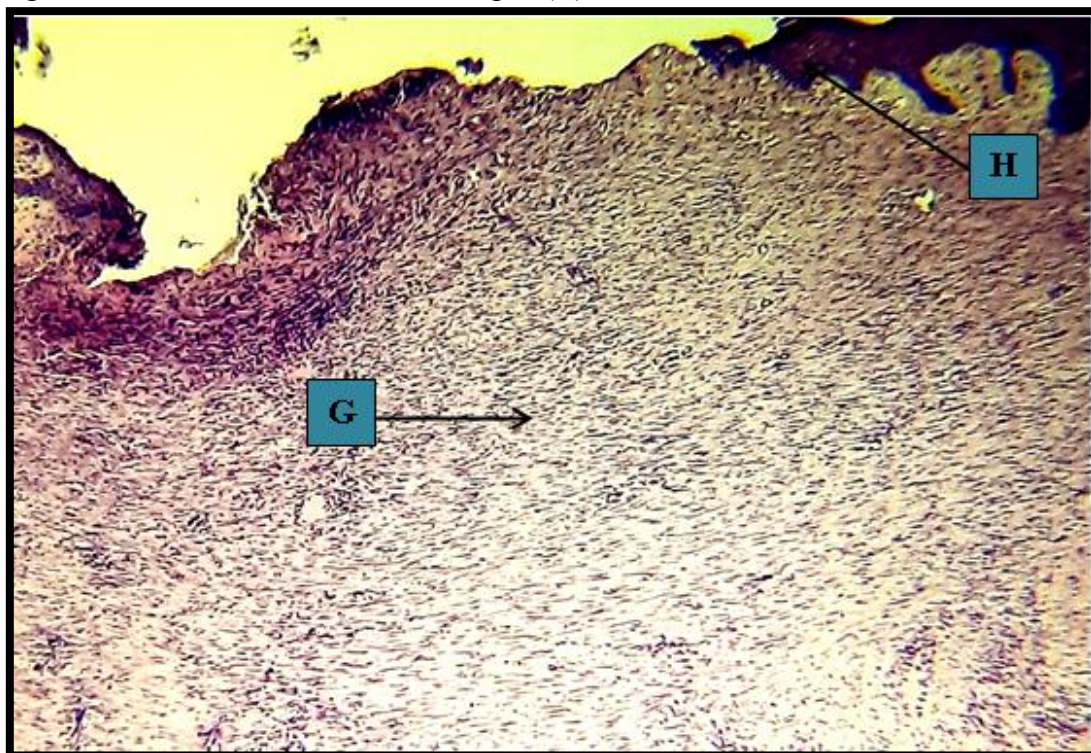


**Figure G1:** Profuse purulent exudate (P) which formed from dead neutrophils and tissue debris and thick crust above the edges of wound. Thin and branched network of collagen fibers (C) and newly formed blood vessels (BV) in the dermis. 10X H&E.

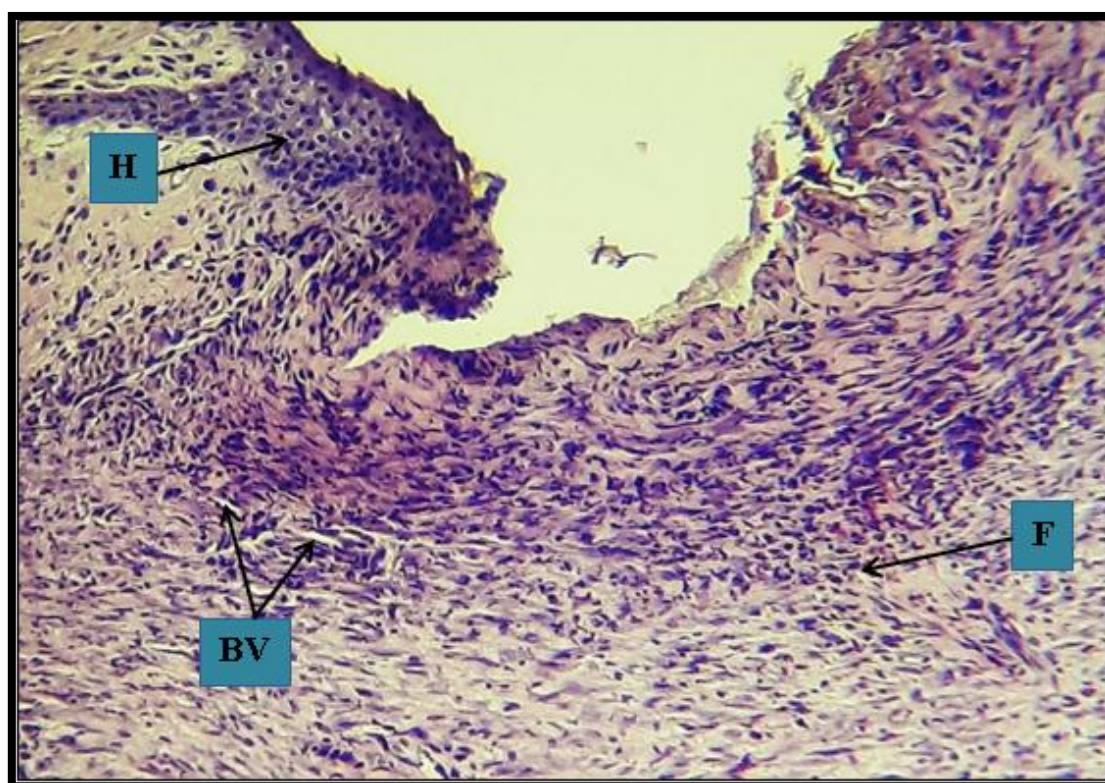




**Figure G2:** Wide scar tissue with profuse granulation tissue (G) in the dermis. Thick crust (CR) with purulent exudate above the epidermis. Few hyperplasia (H) of stratum basal above the edges of wound. Few amounts of collagen (C) in the dermis. 4X H&E.

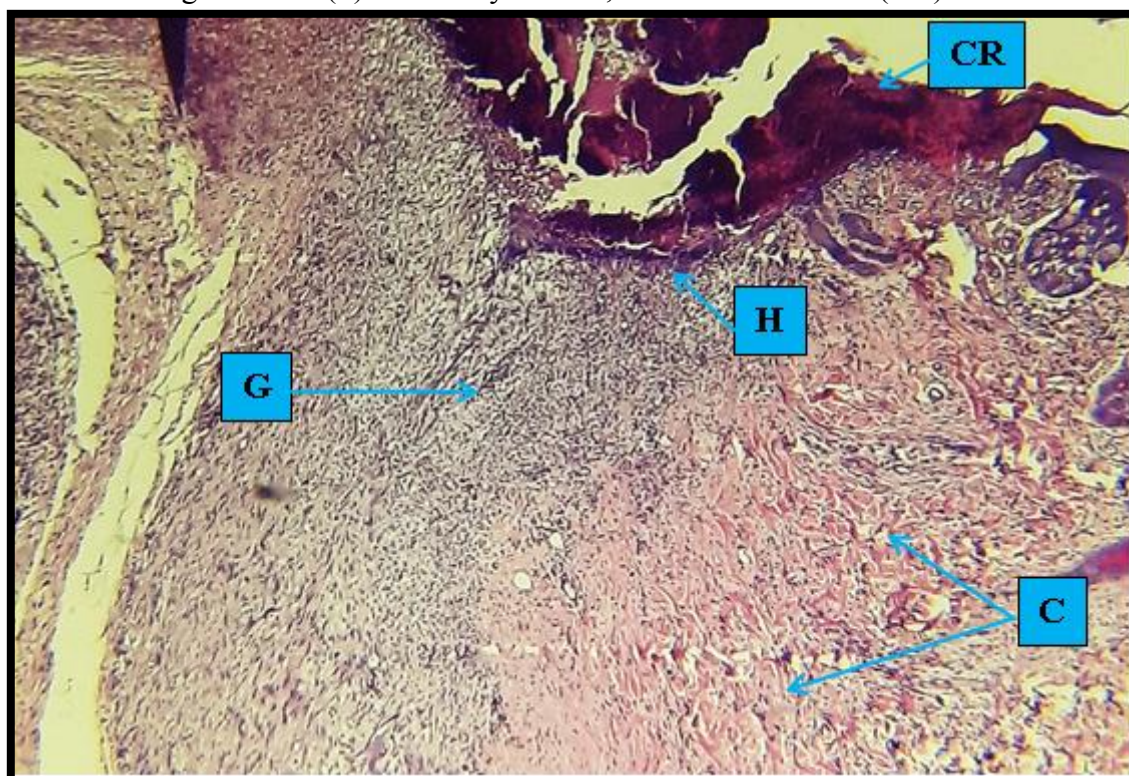


**Figure G1:** Complete sloughing of epidermal layers with slightly hyperplasia (H) on both edges of the wound. Profuse granulation tissue (G) with wide scar tissue. 4X H&E.

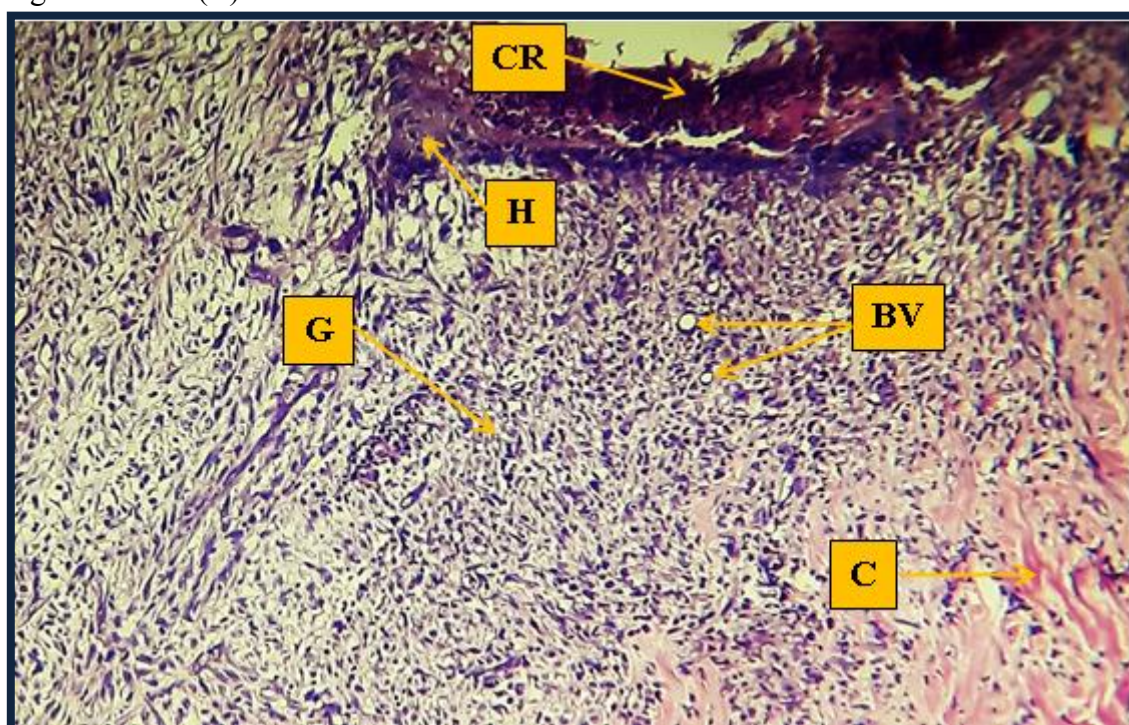




**Figure (6)G1:** Few hyperplasia (H) on the edge of the wound with profuse granulation tissue which contain high fibrosis (F) and newly formed, small blood vessels (BV). 10X H&E.



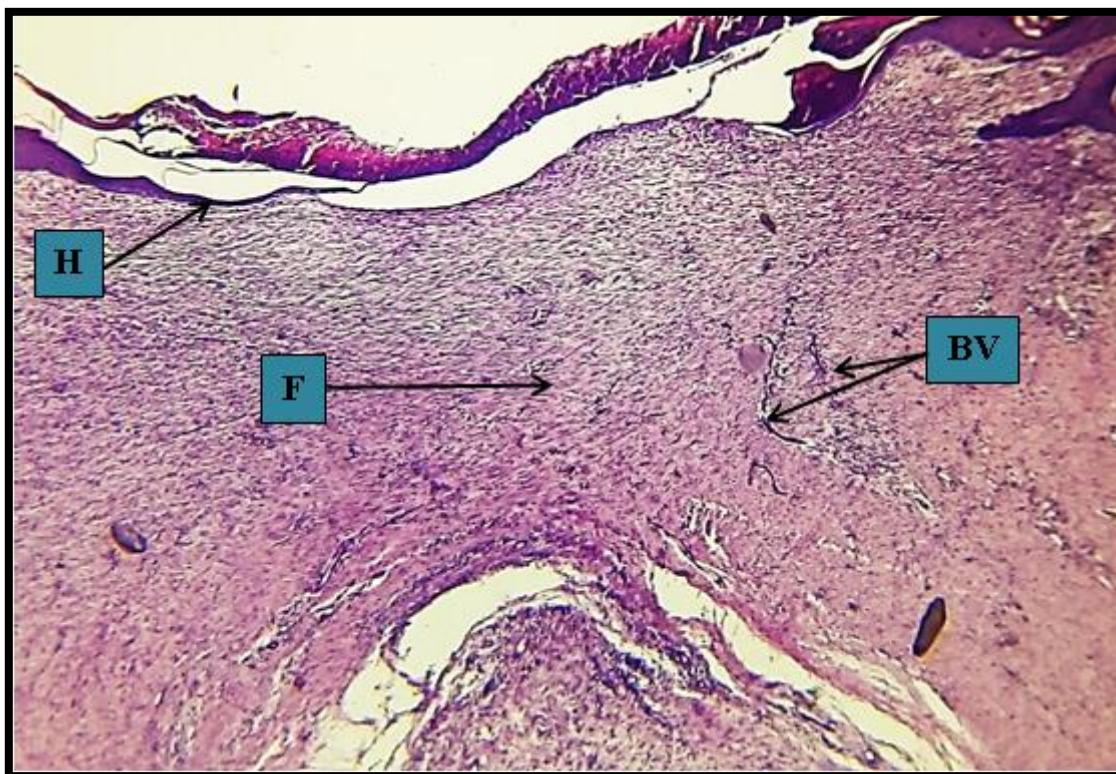
**Figure G2:** Thick cracked crust (CR) above the epidermal layers with few proliferations of stratum basal (H). Profuse granulation tissue (G) and moderate amount of thin branched collagen network (C) in the dermis. 4X H&E.



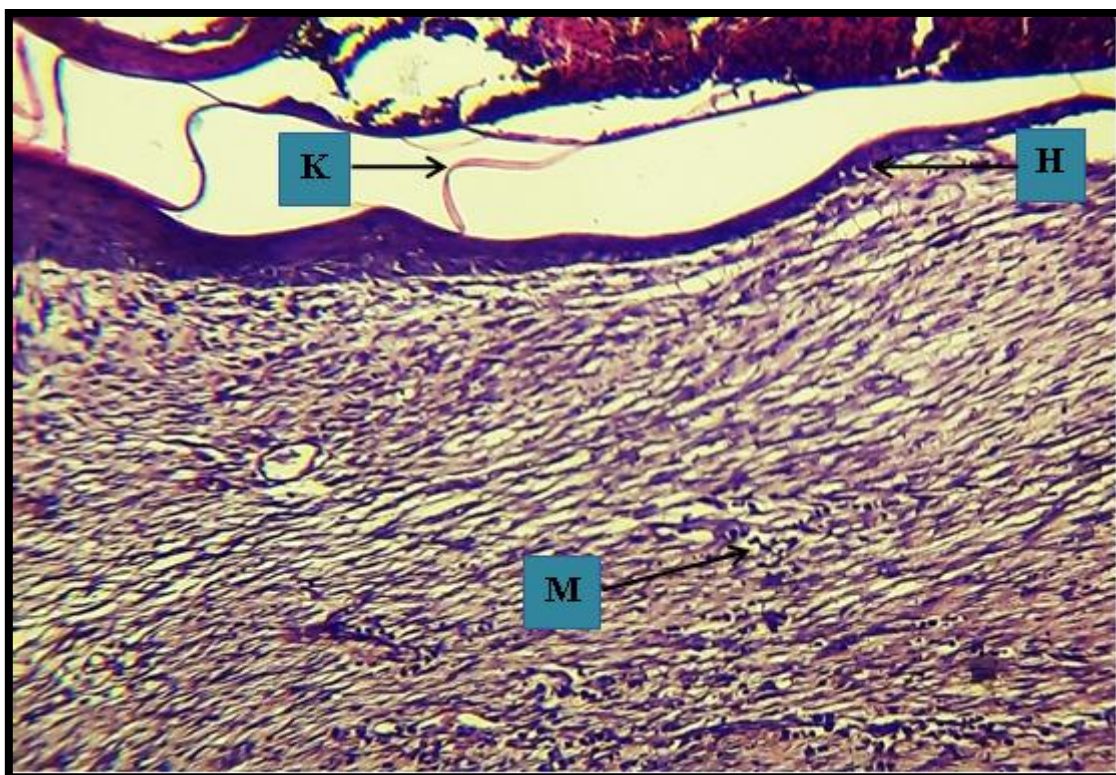
**Figure (8)G2:** Higher magnification. Few proliferations or hyperplasia (H) of stratum basal with thick crust above it (CR). Profuse granulation tissue (G) characterized by new formation



of small blood vessels (BV) with fibrosis and branched network of collagen (C) in the dermis.  
 10X H&E.

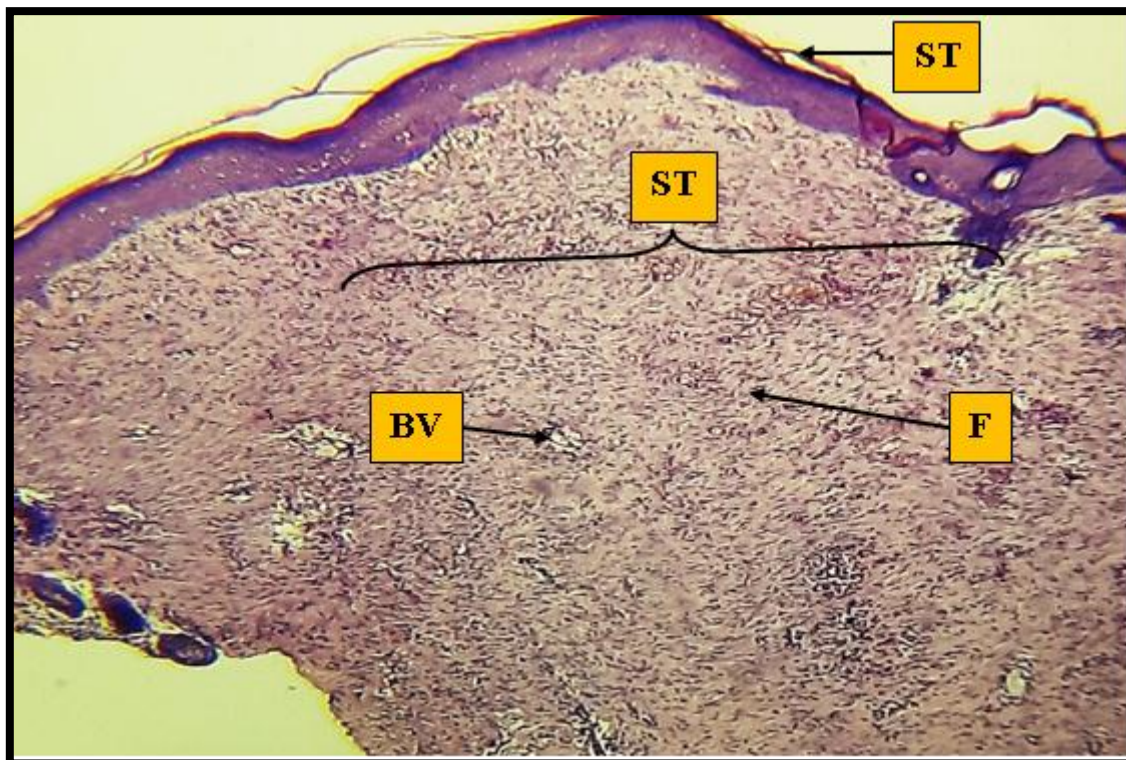


**Figure (9)G1:** Thin and proliferating epidermal layers (H) above the edges of the wound. Wide scar tissue in the dermis with profuse fibrosis (F) horizontally on the wound of the edges and small, newly formed blood vessels vertically on it (BV). 4X H&E.

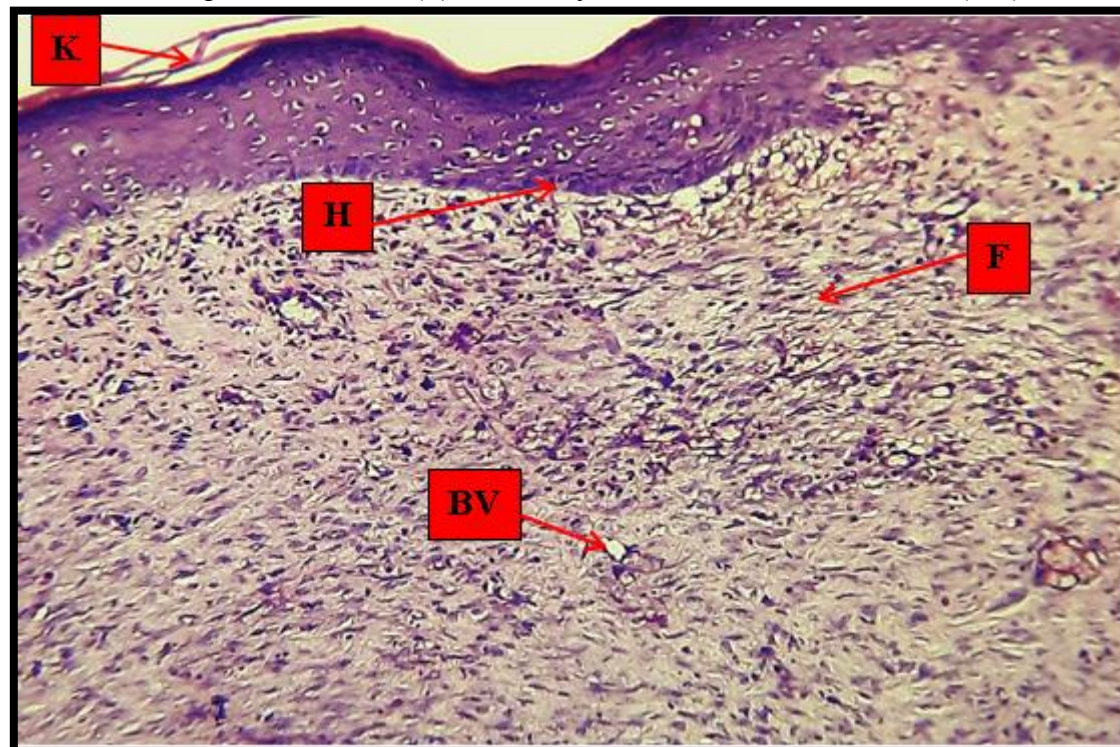




**Figure (10)G1:** New and few hyperplasia of stratum basal (H) with thin keratinized layer above it (K). In the dermis, there is scattered infiltration of macrophages (M) with profuse fibrosis and few blood vessels formation. 10X H&E.



**Figure (11)G2:** Thin keratinized layer (K) and thick epidermal layers. Wide scar tissue (ST) in the dermis with profuse fibrosis (F) and newly formed small blood vessels (BV). 4X H&E.



**Figure (12)G2:** Marked thin keratinized layer (K) with proliferating epidermal layers (H). In the dermis, there are newly-formed small blood vessels (BV) with fibrosis (F). 10X H&E.

## Discussion

The rats served as test animals in this study for two reasons. They picked white rats as test subjects for two main reasons. Initially, rats matured extremely slowly. As a result, elements of physiological, neurological, and psychological development were available to the experimental approach. Secondly, rats were supposed to have exceptionally high sex drives (Logan, 2001). In this study, medicinal herbs were employed to create methods to promote wound healing and minimize bacterial contamination (Edraki et al., 2014).

Saffron (*Crocus sativus*) promotes wound healing through several key mechanisms. Its potent anti-inflammatory properties help reduce excessive swelling and pain at the wound site by inhibiting pro-inflammatory cytokines and enzymes. Additionally, the antioxidants in saffron, such as crocin and safranal, protect tissue from oxidative stress by neutralizing harmful free radicals, preventing cellular damage, and supporting tissue regeneration (Wounds et al., 2008). Saffron also stimulates collagen production, which is essential for repairing and rebuilding the skin's structure. Its antimicrobial properties help prevent infections, ensuring that the healing process is not disrupted by bacteria or other pathogens. Furthermore, saffron supports angiogenesis, the formation of new blood vessels, which ensures an adequate supply of nutrients and oxygen to the wound area, accelerating healing. Finally, saffron's mild analgesic effects may help reduce pain, making the healing process more comfortable. Overall, saffron aids in regenerating all layers of the skin,

reducing scarring, and promoting faster, more efficient wound healing (Alemzadeh & Oryan, 2018).

Clinical assessment of wounds in all animals during the course of the trial revealed that, they were energetic, healthy, active, and had good healing processes at the site of damage. There was no infection in any of the experimental animals' wounds, and no fatalities were reported. Primarily, all wound regions expanded in size within 4 hours after the wound's formation and continued to inflate and grow for the following 24 hours. P.W. with exaggeration of the inflammatory signs, these signs accompanied previous study (Fernández-Guarino et al., 2023). The entire incision was swelled, and the borders of the wounds were raised, red in color, and a thick scab formed on the wound from the second day P.W., which lasted longer than the seventh day. The incision steadily diminished in size until the 21st day, when it transformed into little scar tissue in the shape of a circular or liner. These events look like normal after the surgical interference, these results accompanied with (Masson-Meyers et al., 2020).

The superiority of healing morphology were very clear in G2 than of G1 which indicate the super power of saffron for wound healing as showed in Fig.(1) according to the previous study (Deldar et al., 2021).

In this study there was gradual decrease of wound surface (mm<sup>3</sup>) over the period of the experiment as showed in table -1-. These results were accompanied of (Stupin



et al., 2020)(Ten Voorde et al., 2023). This result might be to confident transition from the exudative inflammation phase to the proliferative one. This was accompanied by the lowest degree of wound tissue leukocyte infiltration, especially in the edges.

The wound contraction % in all groups was clear as showed in table-1-. At the 7th and 14th days, the percentage of wound contraction in G2-treated wounds was substantially higher than in G1.G2 showed the largest percentage of contraction. (Alghabban et al., 2023), These findings were due to recently, various cytokines and growth factors have been discovered as responsible for the healing process, including inflammation, reepithelization, granulation tissue development, and angiogenesis.(Lim & Yoo, 2010).

In addition, (Shahein, 2017) reported that binding to TGF- $\beta$  receptors and then modifying its signal transduction lead to well-organization and normal alignment of new collagen in the treated groups (Salem et al., 2014). (Zeka et al., 2018) At his study on new hydrogels enriched with antioxidants from saffron crocus state that the main problem encountered in the preclinical applications of biomaterials relates to the verification of compatibility with the biological environment and is based on 3 main aspects: -1- morphological compatibility (aspect that concerns the size, shape and mass of the bio- material); -2- functional compatibility (aspect that concerns the role played by the material with respect to the expected role); -3- biocompatibility (takes care of the bio-material chemical and biological nature that can induce damaging alterations in

relation to the biological substrate that is organ or tissue).

The histopathologic evaluation showed the superiority of wound healing G2 at the end of the study than another group. G1 showed new and few hyperplasia of stratum basal with thin keratinized layer above it, In the dermis there were scattered infiltration of macrophages with profuse fibrosis and few blood vessels formation as showed in Fig (10). G2 showed marked thin keratinized layer with proliferating epidermis layers. In the dermis there were newly – formed small blood vessels with fibrosis as showed in Fig (12). These histological features accompanied with the results of (Brown et al., 2024).

**Conclusions:** The treatment of clean open skin wounds in rats with saffron alone results in superior healing compared to the control group.

#### **Recommendations:**

Investigate the impact of saffron on the healing process of chronic open wounds.

#### **References**

- Alara, O. R., Abdurahman, N. H., & Ukaegbu, C. I. (2018). Soxhlet extraction of phenolic compounds from Vernonia cinerea leaves and its antioxidant activity. *Journal of Applied Research on Medicinal and Aromatic Plants*, 11(July), 12–17. <https://doi.org/10.1016/j.jarmap.2018.07.003>
- Alemzadeh, E., & Oryan, A. (2018). Effectiveness of a Crocus sativus extract on burn wounds in rats. *Planta Medica*, 84(16), 1191–1200.
- Alghabban, H. M., Saleem, N. H., & Ali, E. M. T. (2023). Assessment of Skin Wound Healing Potentiality of the Topical Prosopis Juliflora Leaf Extract Vs. Sulphadiazine in Male Albino Rat; Histological and Immunohistochemical Study. *Minia*

- Journal of Medical Research*, 34(3), 57–73.
- Bergfelt, D. R. (2008). Anatomy and Physiology of the Mare. *Equine Breeding Management and Artificial Insemination, Second Edition*, 113–131. <https://doi.org/10.1016/B978-1-4160-5234-0.00011-8>
- Brown, M., Williams, A., Chilcott, R. P., Brady, B., Lenn, J., Evans, C., Allen, L., McAuley, W. J., Beebeejaun, M., & Haslinger, J. (2024). Topically applied therapies for the treatment of skin disease: past, present, and future. *Pharmacological Reviews*, 76(5), 689–790.
- Chhetri, H. P., Yogol, N. S., Sherchan, J., Anupa, K. C., Mansoor, S., & Thapa, P. (2010). Formulation and evaluation of antimicrobial herbal ointment. *Kathmandu University Journal of Science, Engineering and Technology*, 6(1), 102–107.
- Deldar, N., Monsefi, M., Salmanpour, M., Ostovar, M., & Heydari, M. (2021). *Wound Healing Potential of Crocin and Safranin, Main Saffron* (. <https://doi.org/10.31661/gmj.v10i0.1900>
- Edraki, M., Akbarzadeh, A., Hosseinzadeh, M., Tanideh, N., Salehi, A., & Koochi-Hosseiniabadi, O. (2014). Healing effect of sea buckthorn, olive oil, and their mixture on full-thickness burn wounds. *Advances in Skin & Wound Care*, 27(7), 317–323.
- Fernández-Guarino, M., Hernández-Bule, M. L., & Bacci, S. (2023). Cellular and molecular processes in wound healing. *Biomedicines*, 11(9), 2526.
- Ghaith, & Eman. (2024). Toxicity of Highdoses of Copper, Zinc And Vitamin D in Rats' Brain. *Diyala Journal for Veterinary Sciences*, 2(4), 107–110.
- Gupta, A. (2021). Classification of Wounds and the Physiology of Wound Healing. *Wound Healing Research: Current Trends and Future Directions*, 3–53.
- Johnson, T. R., Gómez, B. I., McIntyre, M. K., Dubick, M. A., Christy, R. J., Nicholson, S. E., & Burmeister, D. M. (2018). The cutaneous microbiome and wounds: new molecular targets to promote wound healing. *International Journal of Molecular Sciences*, 19(9), 2699.
- Kolarsick, P. A. J., Kolarsick, M. A., & Goodwin, C. (2011). Anatomy and physiology of the skin. *Journal of the Dermatology Nurses' Association*, 3(4), 203–213.
- L.M. Jabbar and T.A. Abid. (2024). Treatment of infected wounds by using antimicrobial blue light phototherapy. In *Iraqi Journal of Veterinary Sciences* (Vol. 38, Issue 2). <https://doi.org/10.33899/ijvs.2023.141837.3140>
- Lim, J. S., & Yoo, G. (2010). Effects of adipose-derived stromal cells and of their extract on wound healing in a mouse model. *Journal of Korean Medical Science*, 25(5), 746.
- Logan, C. A. (2001). “[A] re Norway rats... things?”: diversity versus generality in the use of albino rats in experiments on development and sexuality. *Journal of the History of Biology*, 34, 287–314.
- Mahmood Ahmed, K. (2023). *Antimicrobial Activity of Zinc Oxide Nanoparticles against bacteria isolated from Goat Wounds*. In *Diyala journal for Veterinary Sciences* (Vol. 1, Issue 4).
- Masson-Meyers, D. S., Andrade, T. A. M., Caetano, G. F., Guimaraes, F. R., Leite, M. N., Leite, S. N., & Frade, M. A. C. (2020). Experimental models and methods for cutaneous wound healing assessment. *International Journal of Experimental Pathology*, 101(1–2), 21–37.
- Öztürk, F., & Ermertcan, A. T. (2011). *Wound healing: a new approach to the topical wound care*. 30(November 2010), 92–99. <https://doi.org/10.3109/15569527.2010.539586>



- Poma, A., Fontecchio, G., Carlucci, G., & Chichiriccò, G. (2012). *Anti-Inflammatory Properties of Drugs from saffron crocus*.
- Salem, M. Y., El-Azab, N. E.-E., & Faruk, E. M. (2014). Modulatory effects of green tea and aloe vera extracts on experimentally-induced lung fibrosis in rats: histological and immunohistochemical study. *Journal of Histology & Histopathology*, 1(1), 6.
- Shahein, A. (2017). Wound healing properties of green tea extract in excision-wounded rats. *Al-Azhar Journal of Pharmaceutical Sciences*, 56(2), 102–114.
- Sharma, S., & Singh, S. P. (2014). Dermatological preparations, formulation and evaluation of various semi-solid dosage form. *Asian Journal of Pharmaceutical Research and Development*, 10–25.
- Stupin, V., Manturova, N., Silina, E., Litvitskiy, P., Vasin, V., Artyushkova, E., Ivanov, A., Gladchenko, M., & Aliev, S. (2020). The effect of inflammation on the healing process of acute skin wounds under the treatment of wounds with injections in rats. *Journal of Experimental Pharmacology*, 409–422.
- Ten Voorde, W., Saghari, M., Boltjes, J., de Kam, M. L., Zhuparris, A., Feiss, G., Buters, T. P., Prens, E. P., Damman, J., & Niemeyer-van der Kolk, T. (2023). A multimodal, comprehensive characterization of a cutaneous wound model in healthy volunteers. *Experimental Dermatology*, 32(7), 1028–1041.
- Wilkins, R. G., & Unverdorben, M. (2013). Wound cleaning and wound healing: a concise review. *Advances in Skin & Wound Care*, 26(4), 160–163.
- Wounds, S. B., Khorasani, G., Hosseinimehr, S. J., & Zamani, P. (2008). *The Effect of Saffron (Crocus Sativus) Extract for Healing of*. 190–195.
- Zeka, K., Ruparelia, K. C., Sansone, C., Macchiarelli, G., Continenza, M. A., & Arroo, R. R. J. (2018). New hydrogels enriched with antioxidants from saffron crocus can find applications in wound treatment and/or beautification. *Skin Pharmacology and Physiology*, 31(2), 95–98.