

Toxicity of Highdoses of Copper, Zinc And Vitamin D in Rats' Brain

Ghaith Z. Hassan AL-Askari¹, Eman H. Yousif Al-Tae¹

¹ Department of Pathology and Poultry Diseases, College of Veterinary Medicine, University of Baghdad, Iraq.

*Corresponding Author: E.mail: ghaithalaskari@gmail.com

Abstract

Aims: The aim of this study was to determine the toxicity of the copper sulfate, zinc sulfate and vitamin D₃ for two periods (45 days and 90 days) on brain of rats.

Methods: Dixon's method was used for the estimation of median lethal doses (LD₅₀). Survival and mortality number for each dose have been noted after 24 hours. Following the determination of the median lethal doses (which were 637 mg/kg, 2.4 g/kg and 13.74 mg/kg b. w. for copper sulfate, zinc sulfate and vitamin D₃ respectively) seventy rats were divided into seven groups and housed in same environment cages. The seven treatment groups were divided into group I (the control group) while group II, III, IV, V, VI and VII were subdivided depending on the dosing regimen, the rats in the second group (Group II) (receiving copper sulfate 1/10 LD₅₀), third group (Group III) (receiving copper sulfate 1/20 LD₅₀), fourth group (Group IV) (receiving zinc sulfate 1/10 LD₅₀), fifth group (Group V) (receiving zinc sulfate 1/20 LD₅₀), sixth group (Group VI) (receiving vitamin D₃ 1/10 LD₅₀), and finally, seventh group (Group VII) (receiving vitamin D₃ 1/20 LD₅₀).

Results: Histopathological examination of brain tissue in group II & group III showed congestion of small blood vessels (B.V.). The brain tissues in group IV and group V showed congestion of small B.V. with edema. Group VI and group VII shows aggregation of mononuclear cells in small foci in the brain. Copper-induced toxicity (1/20 of LD₅₀) changes in the brain were less pronounced in rats treated with copper (1/10 of LD₅₀), the case similar in groups that treated with zinc or vitamin D, compared to rats of control group.

Conclusion: In the present investigation the vitamin D₃ has been found to be more toxic than copper sulfate or zinc sulfate based on the median lethal doses (LD₅₀) values. This study shows that both these trace heavy metals (copper sulfate and zinc sulfate) along with vitamin D₃ can be toxic to organisms at higher levels.

Keywords: Heavy metal salts, brain, female rat

Introduction

Small levels of vitamins and minerals are present in organisms and are mostly necessary for health, survival, and production, as a result of their participation in the structural, catalytic, and regulatory roles of animal, human and several other organisms (1). Essential nutrients cannot be made or synthesized in the human and animal body (organisms), either at all or in insufficient amounts, therefore must be obtained by the diet (2). The vitamins and minerals supplements are products that contain all necessary concentrated nutritional ingredients (3). The dietary supplements are used to enhance the diet and to compensate for any deficiency in essential nutrients in the body (4). Furthermore, instances of supplement toxicity have been documented subsequent to misinterpreting medical recommendations (5). There have been more recorded occurrences of dietary supplement poisoning, which is probably due to the lack of public information regarding appropriate dosage (6). Overuse of nutritional supplements can cause some health problems (7). Furthermore, the majority of ruminant mineral deficits are associated with zinc and copper (8). Because vitamin D₃ is fat soluble, an excess of it can build up in the body and become poisonous (9). Last years, due to improper and excessive use of minerals and vitamins, this study evaluated and ascertained the toxicity of these minerals—zinc and copper—as well as vitamin D₃ in rats as they are widely used, especially after the outbreak of the COVID-19 pandemic (corona virus) (10).

Animals' housing

From a private animal center in Abu Ghraib, Baghdad, Iraq, healthy mature female albino rats weighing between 150 and 210 g aged three months on average were taken. After adaptation for a period of 14 days at the new environment, two experiments were conducted, in the first experiment, the lethal doses (LD₅₀) were determined according to the Dixon's method (11). In the second experiment (sub chronic), seventy rats were randomly split into seven groups (10 rats per group) and housed in cages (five animals per cage).

The groups of study

Seventy female albino rats, *Rattus norvegicus*, ten rats in each group, involved in the experiment (sub chronic), as following.

Group I: This group was regarded as a negative control group.

Group II: A dose of 63.7 mg/kg b. w. (1/10 LD₅₀) of copper sulfate was administered orally to each rat. After 45 days, five rats were sacrificed, and after 90 days, the other five rats were also sacrificed.

Group III: A dose of 31.85 mg/kg b. w. (1/20 LD₅₀) of copper sulfate was administered orally to each rat. After 45 days, five rats were sacrificed, and after 90 days, the other five rats were also sacrificed.

Group IV: A dose of 0.24 g/kg.bw (1/10 LD₅₀) of zinc sulfate was administered orally to each rat. After 45 days, five rats were sacrificed, and after 90 days, the other five rats were also sacrificed.

Group V: A dose of 0.12 g/kg b. w. (1/20 LD₅₀) of zinc sulfate was administered orally to each rat. After 45 days, five rats were sacrificed, and after 90 days, the other five rats were also sacrificed.

Group VI: A dose of 1.374 mg/kg (1/10 LD₅₀) of vitamin D₃ was administered orally to each rat. After 45 days, five rats were sacrificed, and after 90 days, the other five rats were also sacrificed.

Group VII: A dose of 0.687 mg/kg (1/20 LD₅₀) of vitamin D₃ was administered orally to each rat. After 45 days, five rats were sacrificed, and after 90 days, the other five rats were also sacrificed.

Ethical approval

The experiments were done according to the general rules and affirmed by the ethics of animal use in research committee of the College of Veterinary Medicine, University of Baghdad, under the animal utilization protocol certificate P-G/2467, June 11, 2023.

Making stock solutions and dosages

A concentration of 1 g of copper sulfate was used to make the stock solution. It was subsequently diluted with 78.49 milliliters of distilled water (D.W.) to yield a final dosage of either 0.25 milliliters (1/20 LD₅₀) per 100 grams of rat body weight (b. w.), or 0.5 milliliters (1/10 LD₅₀) per 100 grams of rat body weight (b. w.), likewise, a stock solution containing 4.8 g of zinc sulfate was made and diluted with 100 ml of distilled water (D.W.). As a result, the final dosage was determined to be either 0.5 ml (1/10 LD₅₀) per 100 g of rats' body weight (b. w.), or 0.25 ml (1/20 LD₅₀) per 100 g of rats' body weight. The vitamin D₃ solution was a pre-made solution with a concentration of 10,000 IU/ml, or 1 milligram every 4 milliliters. Here, one rat weighing 100 grams requires 0.55 milliliters of this concentration, or 1/10 LD₅₀, or 0.275 milliliters, or 1/20 LD₅₀.

Residual concentration of copper sulfate and zinc sulfate in the brains

The amounts of copper sulfate and zinc sulfate, that present in the brains were measured.

Tissue preparation and digestion

Rats were sedated with chloroform around twenty-four hours after the last dose receiving of copper sulfate and zinc sulfate. The brains of the rats were promptly removed, and two grams of each tissue were then frozen at -20 °C to determine the amounts of copper sulfate and zinc sulfate. Samples were allowed to defrost in an oven before being subjected to 3 ml of H₂SO₄ (99.5 %) and 1.5 ml of perchloric acid (62%). After that, samples were kept at ambient temperature for 24 hours and heated to 45 °C on a sand bath for six hours. This was done in preparation for the measurement of copper sulfate and zinc sulfate. After filtering the tissue homogenate, the volume was changed to 25 milliliters. Once more, combine the solutions and dilute to 25 milliliters. Then, measure the sample absorbance in 10-millimeter cells using a reagent blank. Following that, the levels of copper sulfate and zinc sulfate in the digested tissues were measured using atomic absorption at UV-240 using quartz cells.

Histopathological Examination

The procedures of Bancroft (12) were followed for the histopathological observations. The brains' samples of rats were fixed in 10 % natural buffer formalin, then dehydrated in 70, 80, 90 and 100 subsequent concentrations of ethanol, cleared in two steps of xylol and embedded in three steps of molted paraffin (58 °C), and sectioned by microtome in 5 mm and stain by hematoxylin and eosin stain for microscopic examination (13, 14). Hematoxylin-eosin-stained slides were studied under an optical microscope (Olympus microscope) for evaluating the histopathological changes caused by toxic doses of different compounds in the brains of rats.

Statistical analysis

To find the discrepancies between the various outcomes, a statistical analysis was performed on the results. Using the Windows SPSS (Version 19) statistical program, the sample methods were evaluated using the ANOVA test and the mean (Mean ± S.D.) was found. Significant values were defined as P ≤ 0.05 (15).

Results

Determination of median lethal doses of copper sulfate, zinc sulfate, and vitamin D₃

The median lethal doses (LD₅₀) came out to be 637 mg/kg. b. w., 2.4 g/kg b. w., and 13.74 mg/kg b.w. for copper sulfate, zinc sulfate, and vitamin D₃, respectively.

Residual concentration of copper sulfate and zinc sulfate in the brains

The concentration of copper sulfate was significantly increased in both groups and after both periods, especially in group II, which reached to 2.949±0.434 as compared with control group 2.106±0.333 (Table 1). After 90 days, the concentrations of zinc sulfate in the brain increased significantly in both groups, particularly in group IV, which had a concentration of 8.768±0.942, compared to 6.007±0.626 in the control group (Table 2).

Table 1. Shows the concentrations of copper sulfate in rats' brain tissue after two periods (45 days & 90 days) of sub chronic toxicity with copper sulfate.

Groups	Copper μmol/g After 45 days	Copper μmol/ g After 90 days
Group I	B 1.54±0.33	C 2.106±0.333
Group II	A 2.732±0.38	B 2.949±0.434
Group III	A 2.333±0.42	A 2.672±0.567
LSD	0.520267	0.495922

Letters indicate statistical significance among groups.

Table 2. Shows the concentration of zinc sulfate in rats' brain tissue after two periods (45 days and 90 days) of sub chronic toxicity with zinc sulfate.

Groups	Zinc μmol/L After 45 days	Zinc μmol/L After 90 days
Group I	B 6.742±0.571	B 6.007±0.626
Group IV	A 7.993±0.667	A 8.768±0.942
Group V	A 7.874±0.746	A 8.298±0.745
LSD	0.699998	0.977964

Letters indicate statistical significance among groups.

Histopathological examination of brain

1. Histopathological sections of groups treated with copper shows different lesions. After 45 days, group III (1/20 LD₅₀) shows normal structure of glial cells with mild congestion of

blood vessels (B.V.) (**Fig. 1:A**). After 90 days, cerebrum shows the aggregation of mononuclear cells (MNC), mostly lymphocytes and slight macrophages in small-foci (**Fig. 1:B**). The lesions of group II, after 45 days shows sloughing of ependymal cells (**Fig. 1:C**), after 90 days characterized by congestive small B.V. with edema (**Fig. 1:D**).

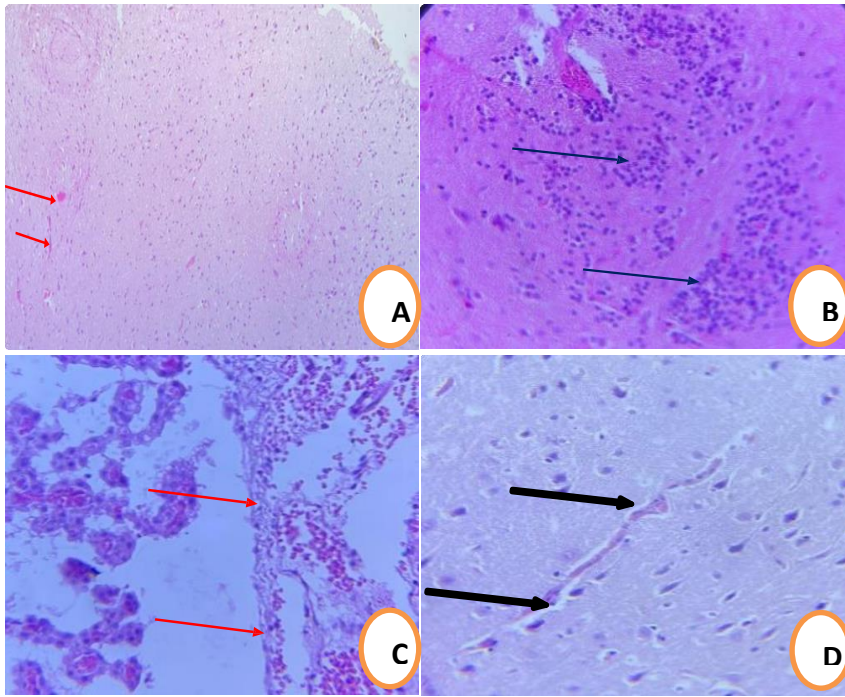


Fig. 1. Histopathological sections of brain tissues of rats treated with copper (group II and group III). (A) Cerebrum cortex shows mild congestion of B.V. (red arrow) (H&E X100). (B) Shows the aggregation of inflammatory cells, mostly lymphocytes and slight macrophages in small-foci (blue arrow) (H&E X400). (C) The ventricle of brain shows the sloughing of ependymal cells (red arrow) (H&E X400). (D) Congestion of small B.V. with cytotoxic edema (black arrow) (H&E X400).

2.Histopathological sections of the brain for groups treated with zinc sulfate shows B.V. congestion and edema appear after 45 days, this lesion being more clearly after 90 days in both group IV and group V (**Fig. 2: A, B, C, D**).

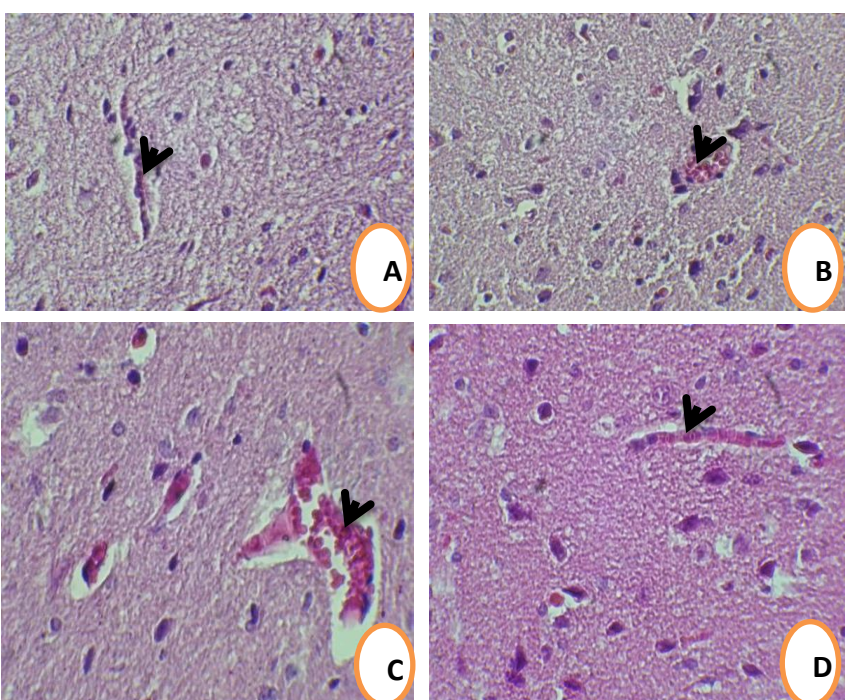


Fig. 2. Histopathological sections of the brain tissues of rats treated with zinc sulfate (group IV and group V). (A) Brain shows congestion of small B.V. with edema (black arrow) (H&E X200). (B) Brain shows congestion of small B.V. with cytotoxic edema (black arrow) (H&E X200). (C) Brain shows congestion of small B.V. with cytotoxic edema (black arrow) (H&E X200). (D) Brain shows congestion of small B.V. with cytotoxic edema (black arrow) (H&E X200).

(H&E X400). (D) Brain shows congestion of small B.V. with cytotoxic edema (black arrow) (H&E X400).

3.Histopathological sections of the brain tissues of rats treated with vitamin D₃ shows aggregation of proliferating microglial cells referred to as a microglial nodule appear after 45 days in group VI (**Fig. 3:A**), with edema clearly after 90 days in both group VI (**Fig. 3:B**) and group VII (**Fig. 3:C, 3:D**).

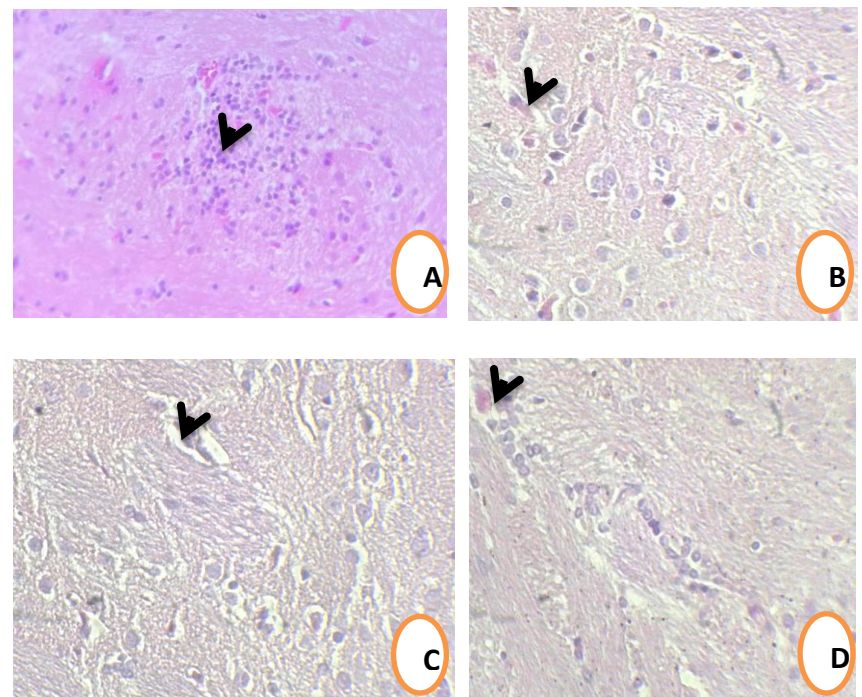


Fig. 3. Histopathological sections of brain tissues of rats treated with vitamin D₃ (group VI and group VII). (A) Shows aggregation of proliferating microglial cells referred to as a microglial nodule (black arrow) (H&E X200). (B) Shows congestion of small B.V. with edema (black arrow) (H&E X400). (C) Shows congestion of small B.V. with cytotoxic edema (black arrow) (H&E X400). (D) Shows congestion and cytotoxic edema of B.V. (black arrow) (H&E X400).

Discussion

Cerebral cells showed, congestion, and infiltration of inflammatory cells. Hashem *et al.* proposed that prolonged or high doses of copper may impair function and intensify intoxication (16). Copper's harmful effects may be the cause of brain damage (17). Low or high copper levels cause a loss of the mitochondrial membrane potential and ultrastructural alterations in brain mitochondria (18). Given that mitochondria are a primary target of copper, may potentially become pertinent in cases of acute or chronic copper overdose (19). Zinc concentration rises due to the dissolution of loosely bound zinc from metalloproteins, which are necessary to maintain the quantity of zinc in the brains, by brain damage-mediated oxidative stress (20). Increased intracellular zinc acts as an ionic regulator of excitotoxic neuronal damage (21). Increased intracellular zinc is excessively taken up and stored by intracellular organelles such as mitochondria, lysosomes, and the endoplasmic reticulum. It could alter the permeability of the blood-brain barrier and enter the brain, severely affecting the functioning of the nervous system. (22). Toxic effects of prolonged exposure to vitamin D₃ are due to disturbing the calcium and phosphorous homeostasis and leading to histopathological changes in vital organs (23).

Conclusion

According to the literature and our findings, exposure to zinc, copper and vitamin D₃ especially at higher doses, may produce toxic effects on various tissues and organs including the brain.

References

1. Ponnampalam, E. N., Kiani, A., Santhiravel, S., Holman, B. W., Lauridsen, C., & Dunshea, F. R. The importance of dietary antioxidants on oxidative stress, meat and milk production, and their preservative aspects in farm animals: Antioxidant action, animal health, and product quality—Invited review. *Animals*, (2022). 12(23), 3279.
2. Hoque, M., Emon, K., Malo, P. C., Hossain, M. H., Tannu, S. I., & Roshed, M. M. Comprehensive guide to vitamin and mineral sources with their requirements. *Indiana Journal of Agriculture and Life Sciences*, (2023). 3(6), 23-31.
3. Kozuharov, V. R., Ivanov, K., and Ivanova, S. Dietary supplements as source of unintentional doping. *BioMed research international*, (2022). (1), 8387271.
4. Woźniak, D., Przysławski, J., Banaszak, M., & Drzymala-Czyż, S. Dietary Supplements among Children Ages 0–3 Years in Poland—Are They Necessary?. *Foods*, (2022). 12(1), 16.
5. Dores, A. R., Peixoto, M., Castro, M., Sá, C., Carvalho, I. P., Martins, A., ... & Marques, A. Knowledge and beliefs about herb/supplement consumption and herb/supplement–drug interactions among the general population, including healthcare professionals and pharmacists: A systematic review and guidelines for a smart decision system. *Nutrients*, (2023). 15(10), 2298.
6. Augustsson, A., Qvarforth, A., Engström, E., Paulukat, C., & Rodushkin, I. Trace and major elements in food supplements of different origin: Implications for daily intake levels and health risks. *Toxicology reports*, (2021).8, 1067-1080.
7. Hassen, G., Belete, G., Carrera, K. G., Iriowen, R. O., Araya, H., *et al.*, Clinical implications of herbal supplements in conventional medical practice: a US perspective. *Cureus*, (2022). 14(7).
8. Byrne, L., and Murphy, R. A. Relative bioavailability of trace minerals in production animal nutrition: A review. *Animals*, (2022). 12(15), 1981.
9. Janoušek, J., Pilařová, V., Macáková, K., Nomura, A., Veiga-Matos, J., Silva, D. D. D., Remião, F., Saso, L., Malá-Ládová, K., Malý, J., Nováková, L., and Mladěnka, P. Vitamin D: Sources, physiological role, biokinetics, deficiency, therapeutic use, toxicity, and overview of analytical methods for detection of vitamin D and its metabolites. *Critical reviews in clinical laboratory sciences*, (2022). 59(8), 517-554.
10. Baiomy, A., & Ibrahim, M. Effect of vitamin d, zinc and copper supplements to enhance treatment of COVID-19 patients. *Indian Journal of Scientific Research*, (2020). 11(1), 95-100.
11. Dixon W J. The up-and-down method for small samples. *JASA*.(1965). 60(312): 967-978.
12. Bancroft J D, Gamble M . Theory and practice of histological techniques. Elsevier health sciences. (2008). 1-13.
13. Mahmood, M. A. .. Effect of Ascorbic Acid on Hemato-Histopathological changes induced by Diclofenac Sodium in local Male Rabbits. *Diyala Journal for Veterinary Sciences*, (2023) 1(2), 23–37. <https://djvs.uodiyala.edu.iq/index.php/djvs/article/view/96>
14. Humadi, A. A. ., & Minnat, T. R. .. The Hematological and Histopathological changes of *Giardia duodenalis* on the intestine in Diyala Government. *Diyala Journal for Veterinary Sciences*, (2023) 1(1), 66–84. <https://djvs.uodiyala.edu.iq/index.php/djvs/article/view/86>
15. Kim T K. Understanding one-way ANOVA using conceptual figures. *Korean J Anesthesiol*. (2017). 70(1):22-26.
16. Hashem, M. A., Abd El Hamied, S. S., Ahmed, E. M., Amer, S. A., & Hassan, A. M. Alleviating effects of vitamins C and E supplementation on oxidative stress, hematobiochemical, and histopathological alterations caused by copper toxicity in broiler chickens. *Animals*, (2021). 11(6), 1739.
17. Gromadzka, G., Tarnacka, B., Flaga, A., & Adamczyk, A. Copper dyshomeostasis in neurodegenerative diseases—therapeutic implications. *International journal of molecular sciences*, (2020). 21(23), 9259.
18. Borchard, S., Bork, F., Rieder, T., Eberhagen, C., Popper, B., Lichtmannegger, J., Schmitt, S., Adamski, J., Klingenspor, M., Weiss, K. and Zischka, H. The exceptional sensitivity of brain mitochondria to copper. *Toxicology in Vitro*, (2018). 51, 11-22.
19. Sailer, J., Nagel, J., Akdogan, B., Jauch, A. T., Engler, J., Knolle, P. A., & Zischka, H. (2024). Deadly excess copper. *Redox biology*, 103256.
20. Koh, J. Y., Suh, S. W., Gwag, B. J., He, Y. Y., Hsu, C. Y., Choi, D. W. The role of zinc in selective neuronal death after transient global cerebral ischemia. *Science* (1996). 272:1013–1016.
21. Hwang, J. J., Lee, S. J., Kim, T. Y., Cho, J. H., Koh, J. Y. Zinc and 4-hydroxy-2-nonenal mediate lysosomal membrane permeabilization induced by H₂O₂ in cultured hippocampal neurons. *J Neurosci* (2008). 28:3114–3122.
22. Schoofs, H., Schmit, J., & Rink, L. Zinc toxicity: understanding the limits. *Molecules*, (2024). 29(13), 3130.
23. Kumar, R., Banga, H. S., & Brar, R. S. Effects of Dietary Vitamin D₃ Over-Supplementation on Broiler Chickens' Health; Clinicopathological and Immunohistochemical Characteristics. *Journal of Veterinary Physiology and Pathology*, (2023). 2(2), 20-31.