

## **Morphometric Comparative Study of the Pancreas between the Owl Bird and the Moorhen Bird**

Noor Assim Farhan<sup>1</sup> , Ahmed Abdulla Hussein<sup>2</sup>

<sup>1,2</sup>Collage of Veterinary Medicine /University of Diyala

Correspondence E-mail: [ahmed.a@uodiyala.edu.iq](mailto:ahmed.a@uodiyala.edu.iq)

### **Abstract**

The aim of this study was to discover the characteristic features of the pancreas between two different birds. Twenty adult healthy owl birds and moorhen birds, ten individuals per group, were obtained from the local bird market (Algazal Market in Baghdad), regardless of their sex. Birds were euthanized via injection muscularly of ketamine and xylazine anesthetics ( 25.5 mg/kg) of body weight. The results showed that the owl Pancreas. The owl Pancreas was located in the coelomic cavity between the two limbs of the duodenum. The pancreas's color of ranged from white to creamy and it had wide to flat shape . The owl pancreas consisted of three lobes: the dorsal, ventral, and third. There are well-built interlobar networks that make it difficult to distinguish among the three lobes. In owls, the pancreas was tightly attached to the blood vessels and mesentery, as well as its relationship to the gizzard, liver, and spleen, holding the pancreas in place. The pancreas of moorhens exhibited an elongated, strand-like structure. The pancreas of this bird. It is composed of four lobes: ventral, dorsal, third, and splenic. The color of the pancreas is light pink.

**Key words: pancreas, owl, lobes, moorhen**



This is an open access article licensed under a [Creative Commons Attribution-Non-Commercial 4.0 International License](https://creativecommons.org/licenses/by-nc/4.0/).

## Introduction

The Owl prefers weathered old barns to nest in nonetheless will also nest in dead trees and rock gaps. Barn

Owls have rounded face with a white, heart-shaped with a clearly defined disc lined with short, stiff, slightly swelled feathers. The owl eyes appear as small, dark and close set. It has skinny legs, and the superior part of the body is an orange-buff, delicately dotted with grey brown and white (1).

The moorhens are little duck-sized water birds that inhabit water shelves, riverbanks, and reed-filled areas. They are distinguished by a red or white tint

on their foreheads. In the Arab homeland, the moorhens can be found in Egypt, Morocco, Syria, and stretch east to Iraq, the Arab gulf up to Iran's borders, the middle of Asia, and the majority of European nations. The

common moorhen, scientifically known as *Gallinula chloropus*, in addition to being called the "waterhen" or "swamp chicken" (2).

The pancreas of the kestrel is located beneath the right side of the peritoneal cavity, in the space between the descending part and ascending half of the duodenum, light to snowy pink. It composed of three lobes "dorsal (lobus pancreatic dorsalis), middle (middle pancreatic lobus) and ventral (lobus pancreatis ventralis)" with well-built interlobar connections made it difficult to distinguish between the lobes (3).

The gland of the male ducks consists of three chief lobes (dorsal, ventral, and third lobes). The majority of the pancreas in red jungle fowl composed of four lobes: dorsal, ventral, third

and small splenic . Three pancreatic ducts were documented as they join the proximal end of the ascending duodenum(4).The pancreas of geese was positioned on the right side of the coelomic cavity. It has four lobes- dorsal, splenic, ventral, and third and a characteristic duodenal papilla. Its situated between the ascending and descending duodenal loops ( 5 ) .

Bustard pancreas can appear wherever from light gray to scarlet and is situated in the area between the two limbs of the duodenal loop, the pancreatic and bile ducts both emerge into the ascending area of the duodenum, as opposed to the cranial portion of the gizzard (6). At the end of the duodenum of a pied crow, there are two pancreatic ducts and two bile ducts that both empty close to one another (7). The pancreas is found within the ansa duodenalis and extends close to the cloaca. It is positioned so that it is lying straight on the right abdominal

wall (8). The pancreas of a red jungle fowl (*Gallus gallus spadiceus*) is held in place by the pancreatico-duodenal ligament, which is located between two limbs of the duodenum in this species (4 ). In ducklings, the duodenum is stretched out to its full length (9).

### Materials and methods

Twenty adult healthy owl birds and moorhen birds, ten per group, were obtained from the local bird market (Algazal Market in Baghdad), regardless of their sex. The euthenization of the birds doing by injection of a ketamine and xylazine at dose 25.5 mg/kg of body weight (10) , and then the weight and length were taken. An incision was performed on the coelomic cavity to examine the location, shape, and color of the pancreas, along with its weight and length. It was also inspected in both birds to identify the location and related organs of the pancreas.

## The results and discussion

The owl Pancreas is located in the coelomic cavity between and related to the two limbs of the duodenum. (3, 6) mentioned that in adult Kestrel as well as (11) referred to the same fact. The color of the pancreas was white to creamy and it has wide to flat shape (Fig.1). (12) referred that the native ducks (*Anas Platyrhynchos*) has a small sized and semi-wide pancreas with a light to white pink color, it is situated between the duodenum branches.

The pancreas of owl is consisted of three lobes, dorsal, ventral and third. There are well developed interlobar connections (Fig1). This result accepted by (12). referee that the male duck pancreas consisted of three major lobes (dorsal, ventral, and third lobes).

In this study the pancreas is stable in its position by tightly attached by

mesentery and blood vessels it is related to the gizzard, liver and spleen.

Dorsal and ventral lobes of the pancreas extend from the beginning of duodenal loop to one third length of the duodenum and another small lobe originated from the end of dorsal lobe towards the spleen (Fig.2). Pancreas gland were collected of small and wide lobes there where they are not fill the space in between the two parts of duodenum so, there was a small gap between the duodenal limbs. (Fig. 1).

The pancreas connected with duodenum by two main pancreatic ducts and many small pancreatic ducts. (Fig.3) The mean weight of the owl bird that use in this study was ( $65.3 \pm 0.03$  SE) and the weight of the pancreas was ( $1.1 \pm 1.15$  SE), the relative weight of the owl pancreas was (0.01). The mean Length of the owl bird that use in this study was ( $21.6 \pm 102$  SE) and the length of the pancreas was ( $2.32 \pm 0.10$  SE), the



relative length of the owl pancreas was 0.1(Tab.1). The study demonstrated the elongated and strand-like nature of the moorhen pancreas. The moorhen pancreas consisted of four lobes: ventral, dorsal, third, and splenic lobes(Fig. 3). This result similar to that mentioned by (5) that the pancreas of swan geese possessed four lobes- dorsal, splenic, ventral, (12) referred that the pancreas of the male duck composed of three large lobes (dorsal, ventral, and third lobes).

This mixed gland is prolonged from the fold between the ascending and descending duodenum to the start of the jejunum. It was closely linked to the gizzard, spleen and liver. The color of the pancreas is bright pink. (Fig. 4 ), (12) Implied that the color of the male ducks' pancreas is ranging from pale to white pink, situated between the duodenum branches. The mean weight of the moorhen in this study was  $(200.9 \pm 0.37 \text{ SE})$  gm and the mean

weight of the pancreas was  $(0.7 \pm 0.37 \text{ SE})$  gm. The relative weight of the pancreas was  $(0.003)$  (5) stated that the goose pancreas averaged  $5.72 \pm 0.010$  g. The pancreas were composed of wide lobes there where they are fill the space located between the two limbs of duodenum .(Fig.3 )

Table.1: Anatomical Measurements of the owl and moorhen bird's pancreas.

Bird type	Body weight(gm)	Pancreas weight(gm)	Relative weight	Body length(cm)	Pancreas length(cm)	Relative length
Owl bird	65.3±0.03 SE	1.1 ±1.15 SE	0.01	21.6±102 SE	2.32±0.10 SE	0.1
Moorhen bird	200.9±0.37 SE	0.7±0.37 SE	0.0003	27.2±0.37 SE	2.1±0.03 SE	0.08

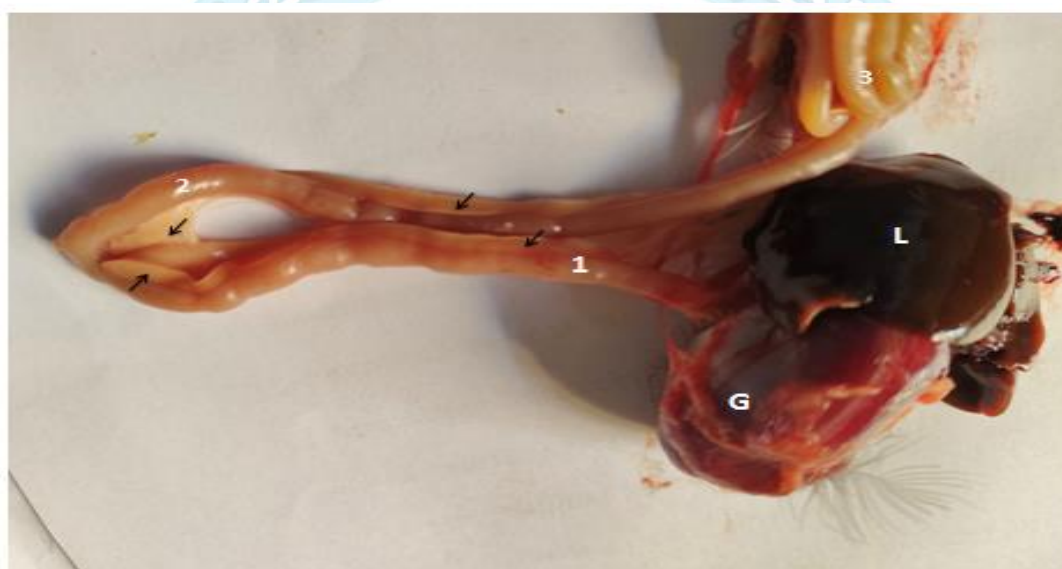

Fig.1.lower digestive system of the owl show pancreas(arrows),ascending duodenum(1),descending duodenum(2),Liver(L),Gizzard(G),Jejunum(3).

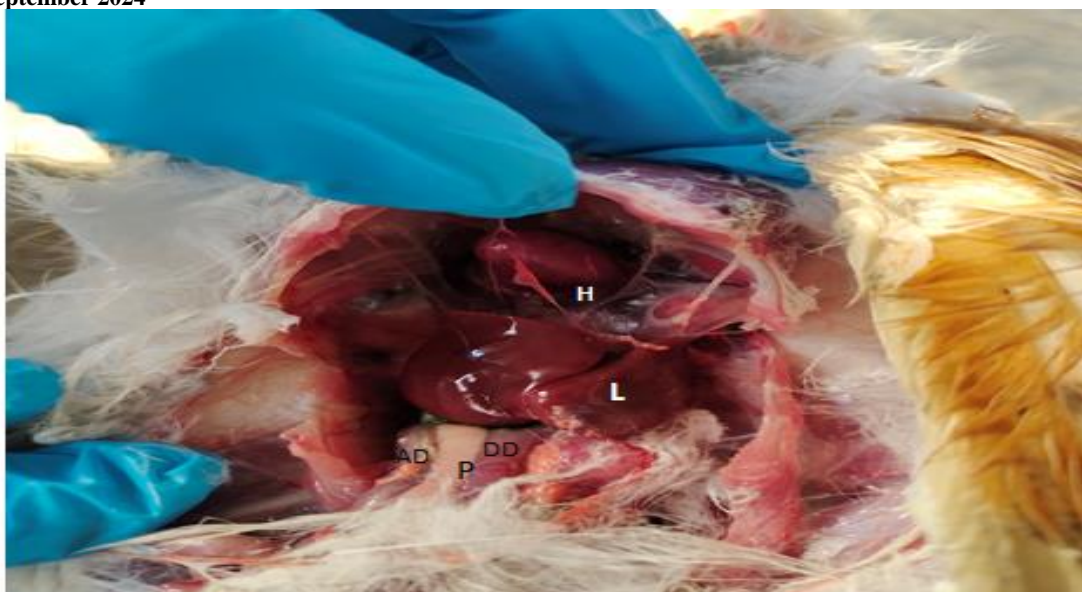


Fig.2.coelomic cavity of the owl show pancreas(p),ascending duodenum(AD),descending duodenum(DD),Liver(L),Heart(H)

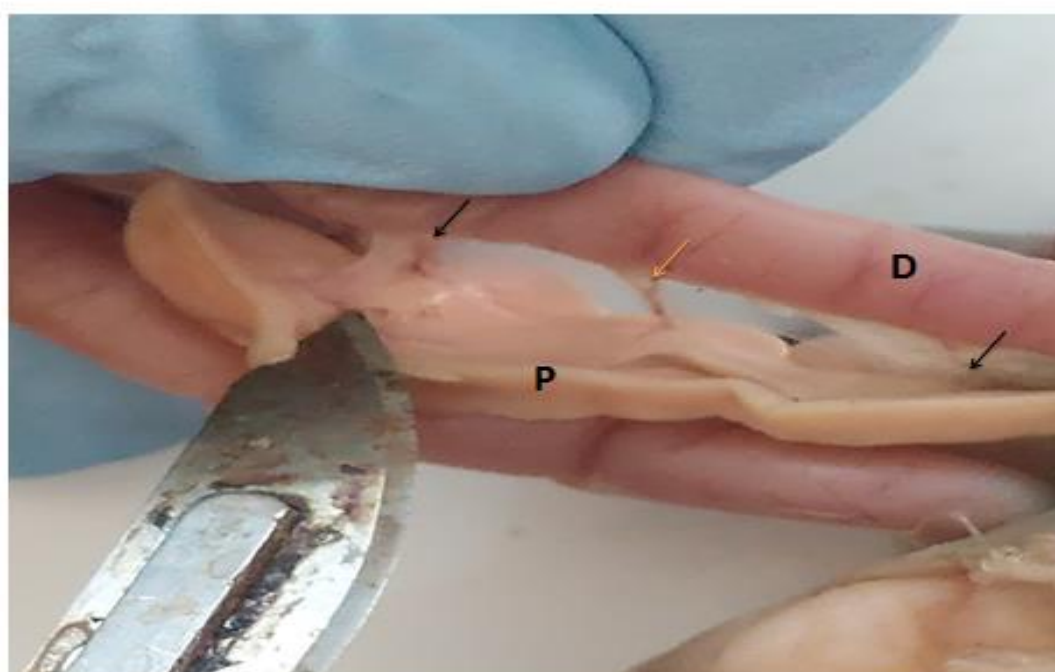

Fig.3. Show pancreas(P) and duodenum(D) of owl ,pancreatic ducts(black arrows),blood vessel(yellow arrow).





Fig.4.lower digestive system of the moorhen bird show pancreas(arrows),ascending duodenum(1),descending duodenum(2),Liver(L),Gizzard(G).

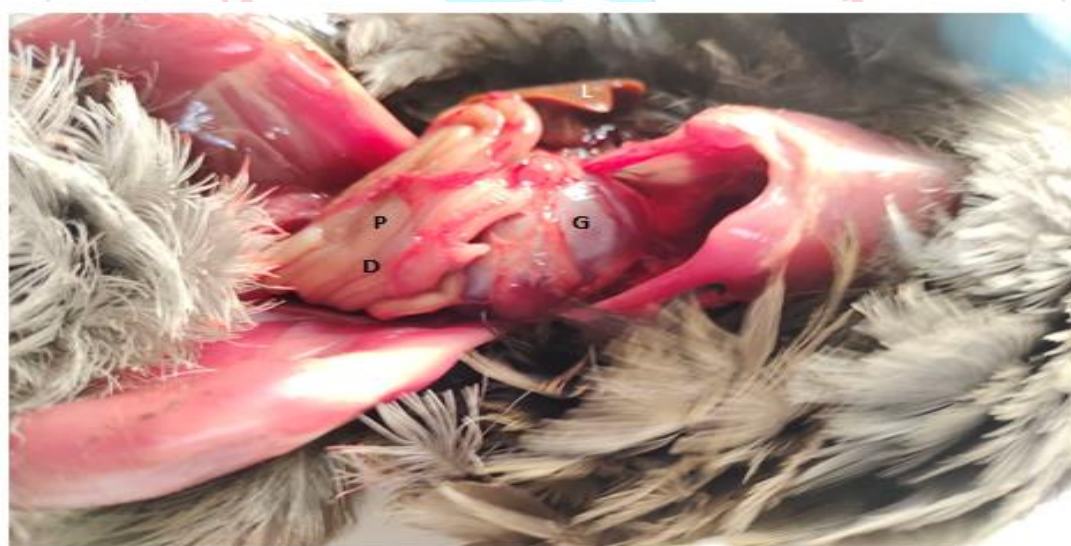

Fig.5. coelomic cavity of the moorhen bird show pancreas(p), duodenum( D), Liver(L),Gizzard(G).



## REFERENCES

1. Bunn, D. S., Warburton, A. B., & Wilson, R. D. (2010). *The barn owl*. A&C Black.
2. Wallau, G. L., Della-Flora, F., Bueno, A. S., Corso, J., Ortiz, M. F., & Cáceres, N. C. (2010). Behaviour of the common moorhen in Rio Grande do Sul, Brazil. *acta ethologica*, 13, 127-135.
3. Al-Haaik, A. (2019). A gross anatomical and histological study of pancreas in adult Kestrel (*Falco tinnunculus*). *Iraqi Journal of Veterinary Sciences*, 33(2), 175-180.
4. Kadhim, K. K., Zuki, A. B. Z., Noordin, M. M., Babjee, S. M. A., & Zamri-Saad, M. (2010). Morphological study of pancreatic duct in red jungle fowl. *African Journal of Biotechnology*, 9(42), 7209-7215.
5. Saad, F. & Dlethe, I. I. (2023). Morphological description of the pancreas in male and female swan geese. *Kufa Journal For Veterinary Medical Sciences* Vol. (14) No. (1) .
6. Jacob, J.; Pescatore, T. and Cantor, A. (2011). Avian digestive system. University of Kentucky, College of Agriculture.
7. Igwebuike, U.H and Eze, U.U. (2010). Morphological characteristics of the small intestine of the African pied crow *Corvus albus*. *Anim.Res.Int*.7:1116-1120.
8. Hristov, H., Vladova, D., Kostov, D. and Dimitrov, R. (2017). Gross Anatomy of some Digestive organs of the Domestic canary (*serinus canari*). *Trakia Journal of Sciences*, 15(2), P : 33-42.
9. Applegate, T. J., Karcher, D. M., and Liburn, M. S. (2005). Comparative development of the small intestine in the turkey poult and pekin duckling. *Poultry science*, 84(3), 426-431.
10. Shindala, M. K. (1999). Anaesthetic effect of ketamine and ketamine with diazepam in chickens.
11. Denbow, D. M. (2015). Gastrointestinal anatomy and physiology. In *Sturkie's avian physiology* (pp. 337-366). Academic Press.)
12. Mahmood, S. K., Ahmed, N. S., Sultan, G. A., & Yousif, M. J. (2022). Histomorphological and carbohydrate histochemical study of the pancreas in native ducks (*Anas Platyrhynchos*). *Iraqi Journal of Veterinary Sciences*, 36(4), 1103-1110.