

Oxidative Status and Histopathological Changes in Broilers Infected with *Salmonella Pullorum* and Treated with *Bacillus Subtilis*, Organic Acids and Ciprofloxacin

Abeer I. Abdulwahhab, Mushtaq T. Baker

Iraq's University of Baghdad's College of Veterinary Medicine

Corresponding author Email: Abeer.Ahmed2107m@covm.uobaghdad.edu.iq *

ABSTRACT

The goal of the study was to compare the effects of three different medications, a probiotic, an organic acid, and ciprofloxacin on oxidant status and histopathological alterations during the starter phase of broiler challenge with *Salmonella pullorum*. A total of 250 (Ross 308) one day old broiler chicks were separated into five groups, each with 50 chicks. All groups, excepted group five, were orally challenged with *Salmonella pullorum* 0.2 ml (25×10^4 CFU/ml) isolate (OM988162.1) at one day old. First group (G1): challenged with *Salmonella pullorum* and treated with *Bacillus subtilis* (2×10^7 CFU/g) (250 g/1000 L) in drinking water; second group (G2): challenged and treated with organic acid (0.5-1 ml/L) in drinking water; third group (G3): challenged and treated with ciprofloxacin 10% (0.5 ml/L) in drinking water; fourth group (G4): challenged without treated as (control positive) and fifth group (G5): unchallenged and untreated as (control negative). The findings indicated an occurrence of highly substantial variations at level ($P \leq 0.05$) of the oxidative status in serum after 7, 21, and 35 days following the challenge with *Salmonella pullorum*, which revealed an increase in the means of H₂O₂ and LPO in serum for all groups in comparison with the control group. When compared to G5, G2 seems to have the greatest mean of antioxidant GSH-px in serum, however, were considerably lower in G4 and G1 at level ($P \geq 0.05$), followed by G3. The histopathological analysis performed at day 21 after infection revealed that *S. pullorum*-a alone infected group (G4) noticed shortening and structural disturbance of the gut, whereas organic acid maintained a mostly unaltered shape and notably boosted intestinal villus height in G2, along with mild perivascular MNCs cuffing and slight hepatocyte vascular degeneration. We conclusion, the organic acid has biggest role in protection compared to ciprofloxacin that have immunosuppression. Also, *B. subtilis* not recorded any protection.

Keyword: GSH-Px, H₂O₂, LPO, Histopathological alterations, *Salmonella pullorum*.



This is an open access article licensed under a [Creative Commons Attribution- NonCommercial 4.0 International License](https://creativecommons.org/licenses/by-nc/4.0/).

INTRODUCTION

A non-motile bird-specific hosts bacteria termed *Gallinarum* serovar *Pullorum* of *Salmonella enterica* subspecies is able to infect young chickens and turkey poults and induce Pullorum disease (PD) (1). One of the characteristics of *S. pullorum* infection, along with the high rates of mortality among hatchling chicks, is the prolonged maintenance in recovered chicks in the absence of clinical illness (2). Omphalitis and yolk sac infections in newly hatched birds are pathological symptoms of PD. Moreover, enteritis, fibrinous typhlitis, and fibrinous serositis can also be seen. Other common

abnormalities include hepatitis and splenitis, which are frequently accompanied by small, white to haemorrhagic necrotic foci and an expanded kidney with a high urate content is also reported (2). Numerous methods, including immunization, antibiotic usage, preventive measures, and others, have been taken to manage the disease in chickens, but they have not been successful. A medication used in chicken farming is ciprofloxacin, which is a broad-spectrum antibiotic, this medication works best against aerobic gram-negative bacteria (3). Members of this medication family stop the development of bacterial cells by forming covalent bonds with topoisomerase IV (par C) and DNA gyrase

(gyrA), which results in double-stranded DNA breaks and cell death (4). However, an important problem with these antimicrobial medicines is acquired resistance. These issues have led poultry experts to focus on non-antibiotic methods to enhance animal performance and intestinal health (5). Alternative growth stimulants include organic acids that have been demonstrated to increase growth performance in chickens and have been utilized in practice for decades (6). According to a number of studies, adding organic acids to chicken diets may have bactericidal effects on *Salmonella* in the ileum, cecum and crop, chicken guts are a natural source of *Bacillus subtilis*, which is known to generate antibacterial compounds like surfactants (7). In broilers exposed to *Salmonella*, *B. subtilis* was demonstrated to enhance growth and antioxidant status (6). Due to the significance of this alternative therapy, a study was done to determine how probiotics, organic acids, and ciprofloxacin affected the liver and intestine's histological alterations and oxidative status after a broiler was challenged with *Salmonella pullorum*.

MATERIALS AND METHODS

Birds used: In this experiment, two hundred and fifty, broiler chicks from the 308 Ross breed at one day old were employed. They were acquired from the local hatchery, Al-Shukur Poultry Company. 50 broiler chicks per group were randomly distributed into five equal groups.

Experimental design and feeding program

With the exception of the fifth group, which was provided with a supplement as a fallow after three days, all groups were orally challenged with *Salmonella pullorum* 0.2 ml (25×10^4 CFU/ml) isolate (OM988162.1) at one day old (8). First group (G1): challenged with *Salmonella pullorum* and treated with *Bacillus subtilis* (2×10^7 CFU/g) (250 g/1000 L) in drinking water; second group (G2): challenged and treated with organic acid (0.5–1 ml/L) in drinking water; third group (G3): challenged and treated with ciprofloxacin 10% (0.5 ml/L) in drinking water; fourth

group (G4): challenged without treatment as (control positive); fifth group (G5): unchallenged and untreated as (control negative). The Newcastle disease live vaccine (NDV) (eye drop B1) was given to the chicks in all groups, with the exception of group five at the age of one day. At 7 and 18 days old, a second dosage of the NDV booster was given by water. Additionally, they received an intermediate-strain IBDV vaccination when they were 14 days old. A daily record of each group's mortality was documented.

Additives used: Acidifier Commercial product (**B.I.O.Acid Liquid**): group of organic acids containing: Lactic acid, Formic acid, Ammonium format, Ammonium propionate, Acetic acid, Propionic acid, Citric acid monohydrate. (Biochem, Germany). Used through drinking water as recommended by manufacturer (0.5 ml/L). Commercial product (**BIO-SAC**): Probiotic Clostat from Kemin Industries, Inc., Des Moines, Iowa, USA, contains live spores of *B. subtilis* (2×10^7 CFU/g) (ATCC PTA-6737). Used through drinking water as recommended by manufacturer (250 g/1000L). Ciprofloxacin product (**Quinocycline product**): Antibiotic was used through drinking water as recommended by manufacturer (0.5 ml/L).

Salmonella challenge protocol

The chickens were exposed to *Salmonella pullorum* throughout this experiment. The strain has a reputation for quickly colonizing the broiler's digestive tract. Prior to and following the injection, the bacteria's vitality was verified. The bacteria, which had been kept at -80°C , were quickly recovered and plated twice for 24 hours at 37 degrees Celsius using *Salmonella-Shigella* agar (SS agar). In sterile, prewarmed Tetrathionat broth, a single colony of the bacteria was added and cultured for 24 hours at 41°C . An additional plate of bacteria was then placed on SS agar. In order to achieve (25×10^4 CFU/ml), the challenge inoculum was diluted. Before and after injection, a count of live bacteria was validated (8).

Bird infection

The challenge was administered orally to all groups of birds on day one, with the exception of the fifth group. Each bird received oral gavages to administer 0.2 ml of the challenge inoculum into the crop lumen.

Parameters

Oxidative status

Using analytical kits, serum was used to calculate hydrogen peroxide (H₂O₂) concentration, total antioxidant capacity (TAC), and lipid peroxidation (LPO) activity (9). In order to get whole collect blood samples, was done five chicks from each treatment were chosen and given jugular vein punctures on days 7, 21, and 35. For 10 minutes, the blood was centrifuged at 5 °C and 3000 rpm. Till time came for analysis, the serum which was collected, put into Eppendorf tubes, and kept at -20 °C.

Liver function assay

Collected the serum from by drawn whole blood from jugular vein and stored at room temperature for 10 minutes before being centrifuged at 1500 rpm, and used to test for the detection of glutathione peroxidase (GSH-Px), alanine aminotransferase (ALT, C009-3-1) and aspartate aminotransferase (AST, C010-2-1) were tested at the Jiancheng Institute of Bioengineering in Nanjing, China, using commercially available kits (10).

Histological analyses of intestinal tissue

For 24 hours, each set of chickens' liver and the intestine tissues (ilium and jejunal) were preserved in 10% formaldehyde before being paraffin-embedded. Hematoxylin and eosin staining was applied to all tissues after they

were sectioned into sections that were 4μm thick. In prior research (11), the precise approach was reported. A microscope was used to view the slides (Nikon 80i, 100x, Tokyo, Japan). Both the cytoplasm and the nucleus were dyed, with the cytoplasm being red and nucleus was stained blue. The program Case Viewer software (3DHISTECH Slide Viewer 2.5, Budapest, Hungary) was used to measure the height of the intestinal villus.

Statistical analyses: The Statistical Analysis System (SAS) was employed to do each and every statistical analysis. As the cut off for statistical significance, $P \leq 0.05$ was chosen as the global value. The standard error of the means \pm (SEM) was used to represent all values.

RESULTS AND DISCUSSION

Oxidative status

Following a challenge with *Salmonella pullorum* for 7, 21, and 35 days, the results of this investigation revealed the fact that were substantial variations at means ($P \leq 0.05$) among the five groups in terms of oxidative state in the blood. All groups noticed a rise in blood H₂O₂, LPO, and liver enzymes (ALT and AST), with G4 and G1 having the greatest means and G3 possessing the middle means. However, G2 reported the lowest serum H₂O₂ mean when compared to control-negative G5. The means of antioxidant GSH-px concentration in serum declined significantly in G4 and G1 at $P \geq 0.05$, coming after G3 in comparison with G5, when G2 appeared to have the highest means (Fig. 1).

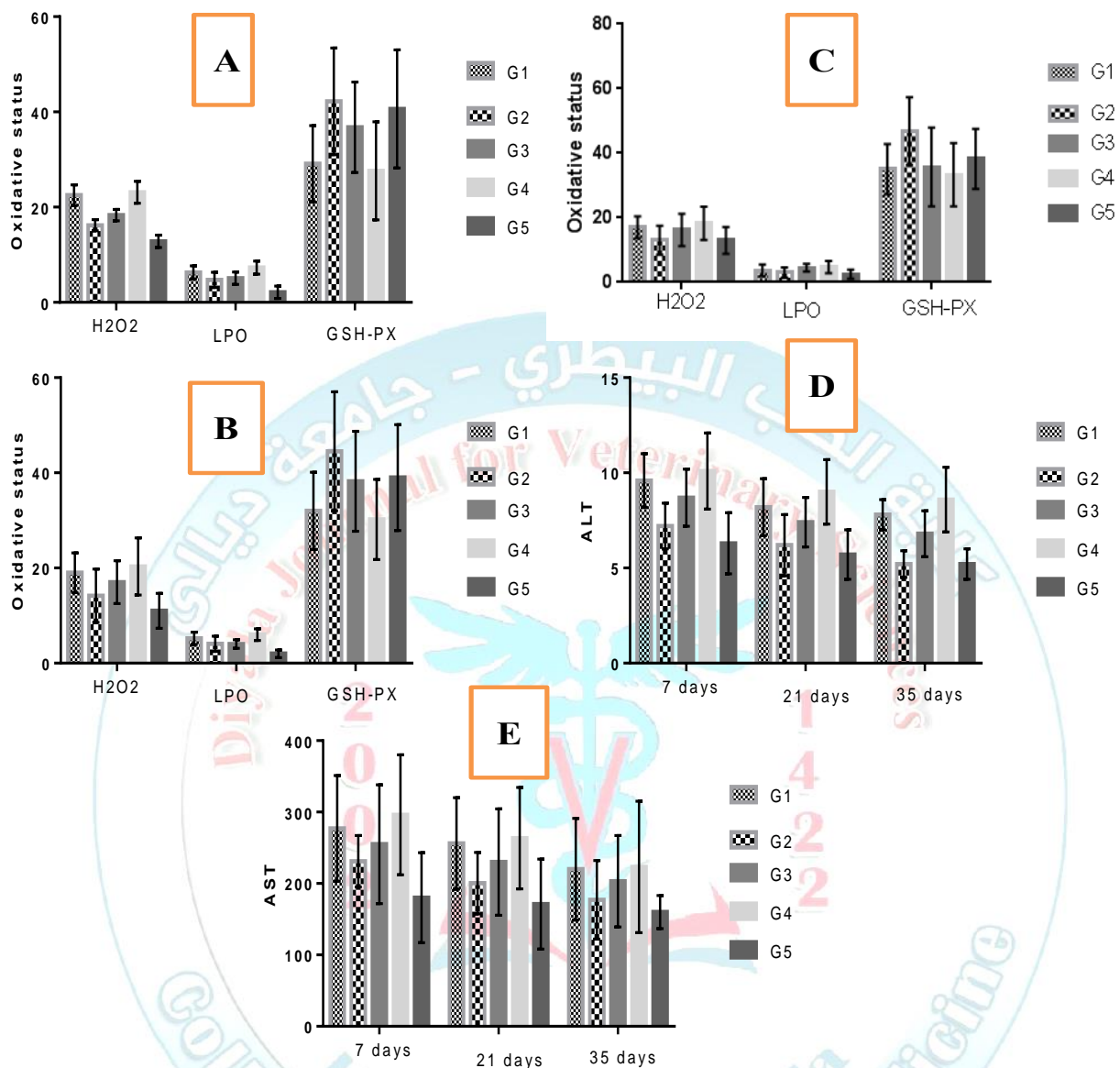


Figure 1. Shows the oxidative status in serum (H₂O₂, LPO and GSH-px). **A:** at 7days; **B:** 21 days; **C:** 35 days. Liver enzymes **D:** ALT; **E:** AST at different periods after challenge with *Salmonella pullorum*.

Salmonellosis-induced elevated oxidative stress resulted in increases in uric acid, creatinine, and Malondialdehyde (MDA) as well as a reduction in Catalase (CAT) and Superoxide Dismutase (SOD) (12). Furthermore, Ismail *et al* (13), reported substantial oxidative stress-related drops in CAT and SOD, as well as rises in serum uric acid, creatinine, and MDA, the body's health is reflected in the serum's antioxidant

capability. Numerous free radicals build up as a result of low antioxidant capacity, which damages cell function (14). In our investigation, supplementation raised blood levels of GSH-Px, a crucial antioxidant enzyme that scavenges oxygen free radicals and safeguards cells' structural and functional integrity, and we found that the amounts of H₂O₂, a marker of toxicity to cells, and LPO, a sign of injury to tissues, increased after *S.*

pullorum infection (15), which are significantly elevated in chicken blood and jejunum tissue, whereas H₂O₂ and LPO were decreased in chicks given organic acid. The G2 group had the lowest mean serum H₂O₂ compared to the other groups. This implies that organic acids protect against oxidative stress. In some studies, by creating an acidic environment in the gut, which encourages the lowering of pH and inhibits the development and multiplication of dangerous bacteria while boosting the growth of helpful bacteria, the addition of organic acid greatly reduced the incidence of *Salmonella*. Pepsin, gastrin, and cholecystokinin are also produced and secreted more readily in an acidic environment, and they are important for nutrient absorption, subsequent growth performance, and feed effectiveness (16). Organic acid had positive influence on *Salmonella* and reduced oxidation stress beside improve serum antioxidant enzymes and MDA (17). Our findings support the research results of Huda et al (18), which showed that broilers' uric acid and creatinine levels increased slightly as a result of organic acid exposure by preventing the generation of intracellular free radicals could play a pivotal role in protecting against liver, kidney, and brain diseases. Antioxidants have the ability to inhibit oxidative stress and free radical formation in our bodies, MDA levels are decreased by propionic acid, whereas CAT and SOD levels are elevated. In the current study, we recognized a considerable rise in (AST) in G4 and G1 throughout the first and second weeks. In a healthy state, the body balances free radical generation and antioxidant production. Nevertheless, in stressful circumstances, the equilibrium changes in favor of free radicals, causing oxidative stress, which can damage proteins, enzymes, DNA, and cellular machinery (19). A damaged or dysfunctional liver is indicated

by the presence of ALT and AST in the serum (20). *S. pullorum* may colonize the liver and spleen as a result of a gut illness, which may later make the colonized organs vulnerable (21). The liver became larger and suffered damage as a result of the *S. pullorum* infection in this study, and the blood levels of AST and ALT that went along with it were significantly greater than those of chickens that were not affected. Contrarily, the adding of 5% acidifier considerably reduced the liver damage induced by *S. pullorum* infection in chicks. This result is connected to the information that organic acid may pointedly reduce the colonization of *S. pullorum* in the gut by reducing the gut PH. The treatments had a substantial influence on GSH-px concentration during the 21- and 35-day periods in the current investigation; though, towards the conclusion of the trial. The oxidative state of the infected group receiving ciprofloxacin and organic acid significantly improved. It is important to note that after exposure to the organic acid, the birds recovered from the stress of infection, (G2) was administered to them. Ciprofloxacin's hydroxyl radical scavenging activity has been linked to its anti-oxidative characteristics (22). Another investigation discovered that broilers that were simultaneously exposed to an organic acid and *S. enterica* subsp. *enterica* typhimurium had a better oxidative state (19), and/or in response to *Saccharomyces boulardii* and *B. subtilis* B10 (23).

Histopathological changes

The histopathological analysis performed 21 days after infection revealed that the *S. pullorum*-alone infected group (G4) noticed shortening of the intestine's villi and structural disturbance, however organic acid in Compared to G4 and G1, G2 kept a mostly intact architecture and significantly higher intestinal villus height ($p \leq 0.05$) (Fig. 2).

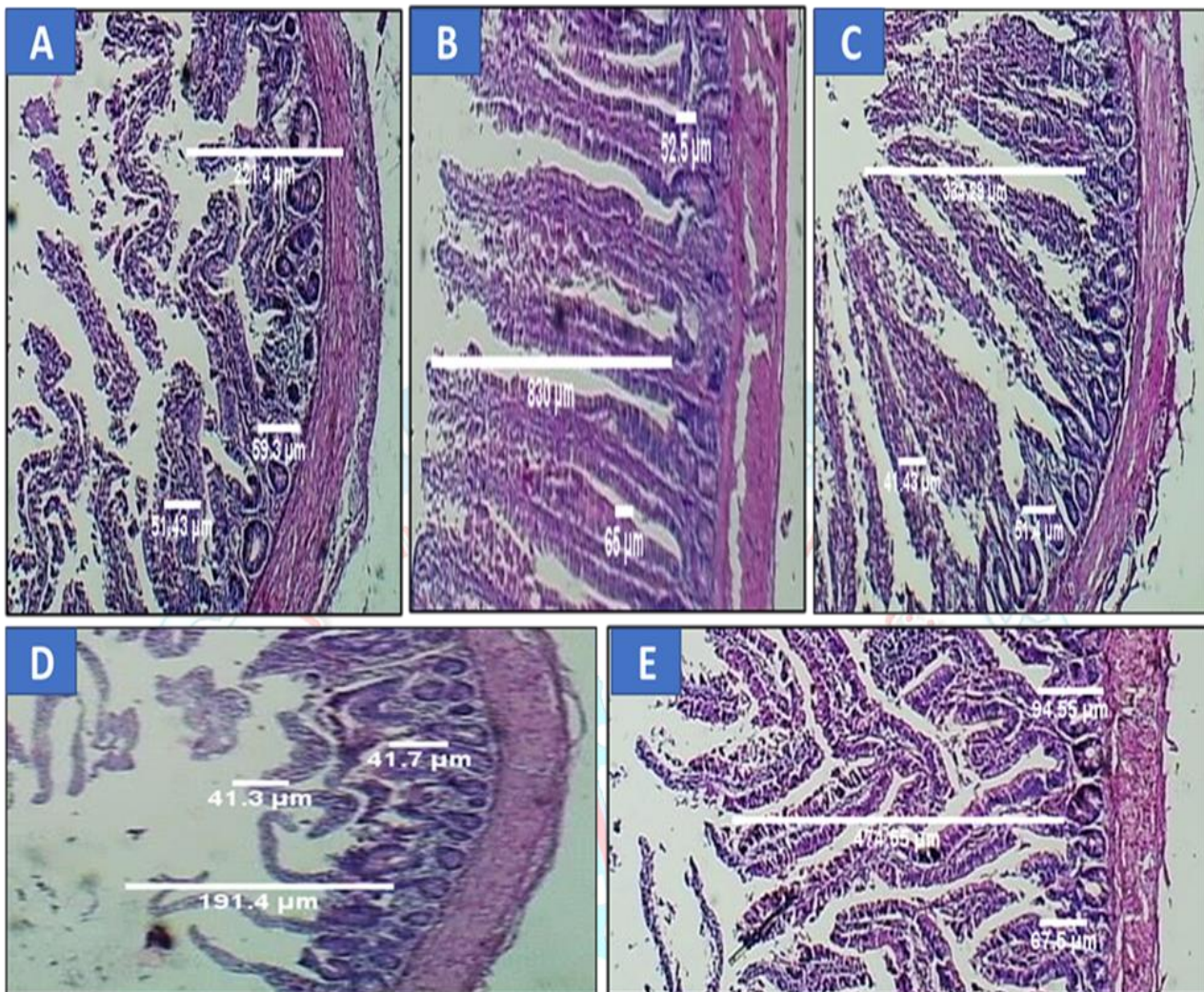


Figure 2. Histopathological examination of the jejunum's (H&E stains, 40X). **A:** Damage of villi of decrease height and width in G1. **B:** The emergence of normal villi dramatically increased the height, width, and depth of crypts G2. **C:** Mild epithelial sloughing of villi slightly increased height, width and depth of crypts G3. **D:** Marked damage of villi with marked decrease of height and width G4. **E:** The villi length, width and depth of the crypts of G5 appear normal.

The histological study revealed that *S. pullorum*-infected chicks ingesting organic acid clearly reduced intestinal villi shortening and structural disruption are clear signs of enteritis. The acidifiers considerably reduced the destruction of intestinal tissues in *S. pullorum*-infected chickens, which is consistent with our findings. These results imply that organic acid could be able to protect chicks against *S. pullorum*. Organic acid has the potential to reduce *S. pullorum* colonization and excretion in the digestive

system, thereby preventing horizontal transmission and environmental pollution, a review of the most recent research, adding organic acid can significantly enhance the intestine's relative weight and length (6,7,25) This intestinal remodeling is consistent with increased relative weights of different gastrointestinal tract segments in broilers given high fiber and corn-resistant starch diets (24). According to research of Iji et al (25), that differences in cell size and the rate of protein synthesis may be the main factors

affecting variations in intestinal weight. Increased intestinal length leads the gut lumen's digestive and absorptive processes to shift from proximal into distal regions improving nutritional absorption (26). According to this study, the ability of the chick gut for digestion and absorption was shown to be increased by organic acid, which may have had a substantial influence on the findings of the lowered feed/gain ratio. Intestinal health can be strongly predicted by the shape of the intestines. Increased villus height and decreased crypt depth are linked to enhanced nutrition absorption throughout the small intestine due to the larger surface area and slower tissue turnover rate (27). The jejunal villus height, crypt depth, and height crypt depth ratio were all significantly reduced in *S. typhimurium*-infected chicks (28), along with severe enteritis. According to Fig. 3, the histological alterations in the liver at 21 days appear to vary between the groups. The liver parenchyma of the G1 group had numerous mononuclear cells MNC infiltrations, mainly surrounding congested blood vessels (bvs.), with heterothallic infiltration and necrotic findings of adjacent hepatocytes showing indications of a granulomatous lesion may recognized either around b.vs with hepatic infiltration or in liver parenchyma that consist mainly of lymphocytes with sinusoids congestion. In G2, it was found that there was mild to moderate perivascular MNC cuffing and modest hepatocyte vascular degradation, but no obvious pathological alterations were seen. There was also mild to moderate vessel dilatation, mostly in the portal vein, and a few

inflammatory cells in the lumen. Large MNC aggregation was observed in G3, along with moderate adjacent parenchymal destruction, ductal dilation, and multiple lymphocytic aggregations. A few sections also displayed minimal portal fibroplasia, portal vein dilation, and congestion. While in G4, liver tissue was observed to have several granulomatous lesions that were mostly focused on portal lesions with ductal damage. Additionally, there was considerable portal fibroplasia and signs of substantial portal vein congestion and dilatation. A ductal hyperplastic response was present along with a noticeable periductal MNC aggregation. However, G5 demonstrated a liver with a normal appearance.

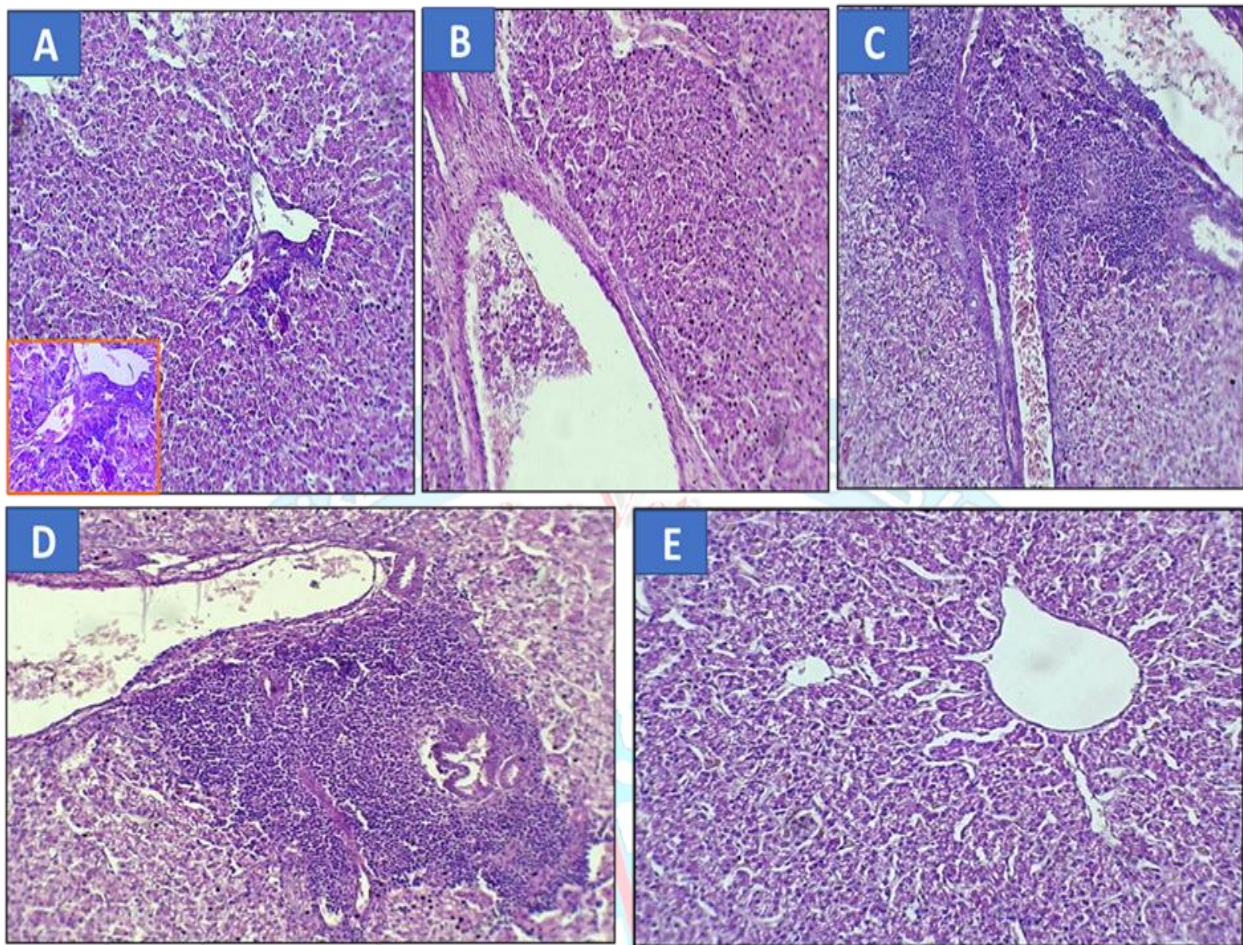


Figure 3. Histopathological examination of the Liver (H&E stain, 200X). **A:** multiple MNCs infiltration in liver parenchyma mainly around congested blood vessels (b.v.s) with heterophilic infiltration and necrotic findings of adjacent hepatocytes in G1 (H&E, 200X). **B:** Liver finding revealed mild to moderate perivascular MNCs cuffing with slight vascular degeneration of hepatocytes. Mild to moderate vessels dilation mainly in portal vein with number of inflammatory cells in the lumen G2 (H&E, 200X). **C:** Large aggregation of MNCs were reported with moderate destruction of adjacent parenchyma with evidence of portal vein dilation and congestion G3 (H&E, 200X). **D:** Multiple granulomatous lesions were reported in liver tissue mainly concentrated in portal lesion with ductal destruction G4 (H.E. X200). **E:** Normal structure appearance in the liver section of control group G5 (H&E, 200X).

The liver lesions of *S. pullorum*-infected birds may look like "White spots," which are not prevalent with *S. gallinarum*, despite the fact that this illness is not pathognomonic (29). Toxins from *Salmonella pullorum* infection in broilers may cause a reduction in serum albumin along with a rise in AST, ALT, and ALP (30, 31). The increased globulin may be brought on by the pathogenic agent's

antigenic stimulation (32). According to Barrow and Neto (33), the principal lymphoid tissues where bacteria exist and develop are the liver and the bursa of Fabricius, which also exhibited the most severe histopathological abnormalities. In this investigation, the liver was affected, and both organs actually had the greatest levels of infection, which is consistent with the results

of an earlier investigation of Nazir et al (34). Hepatocytes with hydropic vacuolation, many necrotic foci, and Kupffer cell hyperplasia were seen together with leucocytic infiltration in the perivascular regions of the liver. Only a few sites of localized macrophage, lymphocyte, and heterophil aggregation were associated with hepatocyte necrosis. Degenerative, necrotic, and infiltrative lesions that are similar have previously been described (35). Broilers' albumin, protein, AST, ALT, and ALP levels increased somewhat as a result of exposure to organic acids (36). The same outcomes were noted by Ezzat et al (37) in broilers treated with formic acid. The total protein and albumin levels of broilers with salmonellosis that received organic acids slightly declined, whereas the levels of globulin, AST, ALT, and ALP somewhat increased (38). By lowering humoral immunity, which involves the production of antibodies, and increasing a cellular response, in which T cells are the main effector cells, enrofloxacin modifies how the immune systems of birds react (39). This was previously discussed with He et al (40) and demonstrates that it alters the way the immune systems of birds react. According to some evidence, some antibiotics, especially enrofloxacin, may harm hens' humoral defense mechanisms while favoring their cell-mediated immunity (41).

CONCLUSION

The authors concluded that in addition to enhancing liver function, organic acids, as opposed to ciprofloxacin, have a significant effect on preventing Salmonellosis in broilers and it is role as a growth enhancer. In broilers exposed to *S. pullorum*, they were treated with (organic acids) successfully used to maintain the oxidative state with few histopathological alterations could occur.

Acknowledgments: The authors would like to thank the Veterinary Medicine College and the Pathology and Poultry Diseases

Department for all the help with facilities during our experiment.

REFERENCES

1. Gast RK, Porter RE. Salmonella infections. In: Swayne DE, Boulianne M, Logue CM, McDougald LR, Nair V, Suarez DL, editors. Diseases of poultry. 14th ed. Hoboken (NJ): Wiley-Blackwell. 2020; p. 719–753.
2. Wigley P, Hulme SD, Powders C, Beal RK, Berchieri Jr A, Smith A, Barrow P. Infection of the Reproductive Tract and Eggs with *Salmonella enterica* serovar *pullorum* in the Chicken is Associated with Suppression of Cellular Immunity at Sexual Maturity. Infect. and Immun. 2005; 73:2986-2990.
3. Abudabos AM, Al-Batshan HA, Murshed MA. Effects of prebiotics and probiotics on the performance and bacterial colonization of broiler chickens. South. Afr. J. Anim. Sci. 2015; 45 (2):419–428.
4. Yurin DV, Balbutskaya AA, Skvortsov VN, Prisnyi AA. Antimicrobial activity of fluoroquinolones in relation to microorganisms isolated from animals. Mezhdunarodnyi vestnik veterinarii. 2018; 3: 63-7.
5. Raza T, Chand N, Khan RU, Shahid MS, Abudabos AM. Improving the fatty acid profile in egg yolk through the use of hempseed (*Cannabis sativa*), ginger (*Zingiber officinale*), and turmeric (*Curcuma longa*) in the diet of Hy-Line White Leghorns. Arch. Anim. Breed. 2016; 59:183–190.
6. Abudabos AM, Alyemni AH, Dafalla YM, Khan RU. Effect of organic acid blend and *Bacillus subtilis* alone or in combination on growth traits, blood biochemical and antioxidant status in broiler exposed to *Salmonella typhimurium* challenge during the

- starter phase. J. appl. Anim. Res. 2017; 45 (4): 538-542.
7. Cengiz O, Koksall BH, Tatli O, Sevim O, Avci H, Epikmen T, Beyaz D, Buyukyoruk S, Boyacioglu M, Uner A, Onol AG. Influence of dietary organic acid blend supplementation and interaction with delayed feed access after hatch on broiler growth performance and intestinal health. Vet. Med. 2012; 57: 515-528.
8. Rusul GH, and Mushtaq TB. Effects Of *Salmonella Pullorum* Infection on Vaccinal Immunity Against Newcastle and Avian Influenza Diseases in Broiler Chickens. Texas Journal of Agriculture and Biological Sciences. 2022; 8:1–6. Retrieved from <https://zienjournals.com/index.php/tjabs/article/view/2287>.
9. Abudabos, A.M., Al-Mufarrej, S.I., Alyemni, A.H., Yehia, H.M., Garelnabi, A.R. and Alotybi, M.N., 2014. Effect of using organic acids to substitute antibiotic growth promoters on broiler chickens performance. J. Food Agric. Environ. 12 (2), 447-451.
10. Chen X, Ishfaq M, Wang J. Effects of *Lactobacillus salivarius* supplementation on the growth performance, liver function, meat quality, immune responses and *Salmonella pullorum* infection resistance of broilers challenged with Aflatoxin B1. Poultry Science. Mar 1; 2022; 101(3):101651.
11. Shen X, Yin L, Ma H, Pan X, Zhang D, Zhao R, Dai Y, Hou H, Hu X. Comprehensive genomic analysis and characterization of a new ST 174 type *Klebsiella variicola* strain isolated from chicken embryos. Infect. Genet. Evol. 2021; 90:104768.
12. Sokoudjou J, Kodjio N, Gatsing D. Antisalmonellal and antioxidant potential of hydroethanolic extract of *Canarium schwanfurthii* Engl. (Burseraceae) in *Salmonella enterica* serovar *typhimurium*-infected chicks. Asian Pac J. Trop. 2019; 9:474-83.
13. Ismail I, Al-Busadah K, El Bahr S. Oxidative stress biomarkers and biochemical profile in broilers fed zinc bacitracin and ascorbic acid under hot climate. American J. of Biochemistry and Molecular Biology. 2013; 3: 202-214.
14. Amevor FK, Cui Z, Ning Z, Shu G, Du X, Jin N, Deng X, Xu D, Tian Y, Zhang Y. Dietary quercetin and vitamin E supplementation modulates the reproductive performance and antioxidant capacity of aged male breeder chickens. Poult. Sci. 2022; 101:101851.
15. Gawel S, Wardas M, Niedworok E, Wardas P. Malondialdehyde (MDA) as a lipid peroxidation marker. Wiad. Lek. 2021; 57:453–455.
16. Sultan A, Ullah T, Khan S, Khan RU. Effect of organic acid supplementation on the performance and ileal microflora of broiler during finishing period. Pak. J. Zool. 2015; 47:635–639.
17. Alaeldein M, Abdullah H, Yousif M, Rifat U. Effect of organic acid and *Bacillus subtilis* alone or together on growth traits, biochemical and antioxidant status in broilers exposed to *S. typhimurium* challenge during starter phase. J. Appl Animal Res. 2017; 45 (1):41-50.
18. Huda S, Hanan M, Abdelkadr E, Musarat A, Iman S, Ramesa S. Antioxidant and hepatorenal protective effects of bee pollen fractions against propionic acid induced autistic feature in rats. Food Sci. Nutr. 2020; 8(9)14–27.

19. Abudabos AM, Al-Mufarrej SI. Effects of organic acid supplementation on antioxidant capacity and immune responses of broilers challenged orally with *Salmonella enterica* subsp. *enterica* typhimurium. South Afr. J. Anim. Sci. 2014; 44 (1):342–349.
20. Tong Y, Yu C, Xie Z, Zhang X, Yang Z, Wang T. Trans-anethole ameliorates lipopolysaccharide-induced acute liver inflammation in broilers via inhibiting NF- κ B signaling pathway. Poult. Sci. 2022; 101:101962.
21. Jesudhasan PR, McReynolds JL, Byrd AJ, He H, Genovese KJ, Droleskey R, Swaggerty CL, Kogut MH, Duke S, and Nisbet DJ. Electron-Beam-Inactivated Vaccine against *Salmonella enteritidis* Colonization in Molting Hens. Avian Dis. 2015; 59:165–170.
22. Kabploy K, Bunyapraphatsara N, Morales NP, Paraksa N. Effect of antibiotic growth promoters on antioxidative and anti-inflammatory activities in broiler chickens. Thai. J. Vet. Med. 2016; 46:89–95.
23. Rajput IR, Li YL, Xu X, Huang Y, Zhi WC, Yu DY, Li W. Supplementary effects of *Saccharomyces boulardii* and *Bacillus subtilis* B10 on digestive enzyme activities, antioxidation capacity and blood homeostasis in broiler. Int J Agric Biol. 2013; 15:231–237.
24. Liu YS, Zhang YY, Li JL, Wang XF, Xing T, Zhu XD, Zhang L, Gao F. Growth performance, carcass traits and digestive function of broiler chickens fed diets with graded levels of corn resistant starch. Br. Poult. Sci. 2020; 61:146–155.
25. Iji PA, Khumalo K, Slippers S, Gous RM. Intestinal function and body growth of broiler chickens on diets based on maize dried at different temperatures and supplemented with a microbial enzyme. Reprod Nutr. Dev. 2003; 43:77–90.
26. Elsenhans B, Caspary WF. Food viscosity as determinant for adaptive growth responses in rat intestine: Long-term feeding of different hydroxyethyl celluloses. Br. J. Nutr. 2022; 84:39–48.
27. Munyaka PM, Echeverry H, Yitbarek A, Camelo-Jaimes G, Sharif S, Guenter W, House JD, Rodriguez-Lecompte JC. Local and systemic innate immunity in broiler chickens supplemented with yeast-derived carbohydrates Poult. Sci. 2012; 91, pp. 2164-2172.
28. Fasina YO, Hoerr FJ, McKee SR, Conner DE. Influence of *Salmonella enterica* serovar typhimurium infection on intestinal goblet cells and villous morphology in broiler chicks. Avian Dis. 2010; 54:841-847.
29. Al-Khalidi AAH. Pathological Changes Induced by Systemic Bacterial Infections of Layer Hens Suffered from Respiratory Signs. Diyala Journal for Veterinary Sciences. 2023;1(2):99-109.
30. Kumar T, Mahajan NK, Rakha NK. Epidemiology of fowl typhoid in Haryana, India. World Poultry Science Journal. 2010; 66: 503-510.
31. Belih S, EL-Hadad F, Amen E, Basiony R. Influence of sodium butyrate on salmonella infection in broilers. Benha Vet. Med. J. 2016; 31(2): 21-32.
32. Al-Khalidi AAH. Histopathological, Metabolic and performance Changes in Laying Hens Affected by Fatty Liver Haemorrhagic Syndrome. DJVS [Internet]. 2023 Sep. 7 [cited 2023 Nov. 12];1(3):45-59.
33. Barrow PA, Neto OF. Pullorum disease and fowl typhoid—new thoughts on old diseases: a review. Avian pathology. 2011; 40(1):1-13.

34. Nazir S, Kamil SA, Riyaz A, Mir MS, Darzi MM, Yasmine KS, Goudar KS. Pathology and colonization of internal organs after experimental infection of broiler chickens with *Salmonella gallinarum* through oral or intraperitoneal routes. 2014; 67(2):53-60.
35. Saha AK, Sufian MA, Hossain, MI, Hossain MM. Salmonellosis in layer chickens: pathological features and isolation of bacteria from ovaries and inner content of laid eggs. Journal of the Bangladesh Agricultural University. 2012; 10(1): 61-67.
36. Adil S, Banday T, Bhat G, Mir M, Rehman M. Effect of supplementation of organic acids on performance, intestinal morphology, and serum biochemistry of broiler chicken. Vet. Med. Inter. J. 2010; 67(6):17.
37. Ezzat H, Shawky N, Hasan A, El Sayed M. Pathological and biochemical studies on effect of formic acid in broilers. Zag. Vet. J. 2015; 43(3):34-43.
38. Jing W, Dong D, Haijun Z, Yuan W, Guang Q. Organic acids modulate systemic metabolic perturbation caused by *Salmonella pullorum* challenge in early-stage broilers. Avian Phyto. 2019; 23(2): 342-349.
39. Kumar VS, Chandra GS, Ramesh J, Vairamuthu S, Thejomoorthy P, Hariharan P. Effect of enrofloxacin administration on haematological profile in broiler chicken-A safety pharmacology study. Indian Journal of Veterinary Sciences and Biotechnology. Dec. 2012; 8(2):20-4.
40. He H, MacKinnon KM, Genovese KJ, Nerren JR, Swaggerty CL, Nisbet DJ, Kogut MH. Chicken scavenger receptors and their ligand-induced cellular immune responses. Molecular Immunology. 2009; 46(11-12): 2218-2225.
41. Laxminarayan R, Heymann DL. Challenges of drug resistance in the developing world. Bmj. 2012; 4(3):332-344.