

Histopathological investigation of tissues from chickens and pigeons infected with avian poxvirus in Diyala governorate

Aisha Faisal and Amer Al-Azzawi

Department Microbiology, College of Veterinary Medicine, Diyala University, Iraq

Corresponding author: E-mail: amer_alazawy@yahoo.com

Abstract:

The virus of the genus Avipox virus, which is a member of the subfamily chordopoxvirinae in the family poxviridae, is the source of the viral disease known as avian pox, which can infect both domestic and wild birds. The two diseases that were seen were diphtheritic and cutaneous. The cutaneous form is distinguished by skin sores on the portions of the bird without feathers. The development of fibronecrotic, proliferative lesions on the mucous membranes of the respiratory and digestive systems distinguishes the diphtheritic form. This study's goal is to look into the pigeons' and chickens' histology avian pox lesions. From October 2022 to March 2023, the current study was carried out at Diyala University's College of Veterinary Medicine. Twenty tissue samples of pigeons (*Columba livia domestica*) and chicken (*Gallus gallus*) from Diyala Governorate's affected vents, eyes, wings, cere, and base of the beak were collected and processed for a histological analysis. The results showed that papules, pustules, or scabs made up the majority of the skin lesions in pigeons. However, in other instances, both single and many nodular growths as well as growths that resembled cauliflower were seen. The bird's eyes, beak, legs, vent, and toes all have these lesions. However, the head and combs were the most common locations for skin lesions in hens. The virus clearly altered the epidermal tissue of pigeon and chicken cutaneous lesions, as evidenced by the hyperplasia of stratified squamous cells with acanthosis and the severe inflammatory exudate containing heterophils, macrophages, and lymphocytes. The stratified squamous epithelium was found to be in a ballooning degeneration stage. The epithelial cells were puffy, round, and scattered widely. Massive eosinophilic inclusions, or Bollinger bodies, were seen in the cytoplasm of hyperplastic epithelial cells, as well as vacuolation, which was constantly present and recognized as ring-shaped eosinophilic

intracytoplasmic inclusions. It was concluded that the avian pox virus resulted in distinct pathological alterations in the cutaneous areas, specifically affecting the epidermal tissues in pigeons and chickens.

Key words: Pigeonpox, Avipoxvirus APVs, histopathological changes, Diyala Governorate



This is an open access article licensed under a [Creative Commons Attribution-NonCommercial 4.0 International License](https://creativecommons.org/licenses/by-nc/4.0/).

Introduction: centrally positioned, electron-

Fowl pox (FP) is an infectious dense core and two lateral bodies viral disease that affects both (2).

domestic and wild birds. It is one Typically, the infectivity is

of the more severe strains of the resistant to ether but vulnerable

poxviridae family and is brought to chloroform. They grow

on by a large group of DNA quickly in cell cultures and on

viruses. It causes mild to severe embryonated eggs'

lesions and has high rates of chorioallantoic membranes,

morbidity and mortality (1). All where they create type A

poxviruses are enclosed, oval- or cytoplasmic inclusions (3). The

brick-shaped viruses. Their linear virus comes in three different

dSDNA genomes range in size strains. These viruses are the

from 250 to 365 kb. The viral ones responsible for canarypox,

particle has a diameter of 270– pigeonpox, and fowlpox.

350 nm and is made up of a

According to Pattison (4), there are two types of the illness: diphtheric/or pharyngeal (wet pox) and cutaneous (dry pox).

The most common variety is the cutaneous or dry type, which manifests as papules, nodules, or scabs on parts of the body without feathers, such as the comb, the area around the beak, the wattles, the eyelids, or even the legs and wings. Mobility, nutrition, and vision may be affected or interfered with as a result of these lesions developing into ulcers. There is no visible scarring left behind when the skin lesions have recovered and healed. Mortality rates are often

low if the cutaneous form predominates (5, 6, 7).

The development of white opaque nodules or yellowish patches on the mucous membranes of the oral cavity, tongue, esophagus, or upper trachea distinguishes the diphtheritic form, which is more severe and causes significant mortality and economic losses in affected flocks (8).

The membrane that results from the fast growth and frequent consolidation of nodules is yellow, cheesy, necrotic, pseudo-diphtheritic, or diphtheritic. Birds of all sexes, ages, and breeds are affected by the disease, which is pervasive

around the world. A number of vectors, including biting arthropods like mosquitoes and mites, aerosols released by afflicted birds, and consumption of tainted food or water, can transmit the disease known as avian pox (9, 10)

Almost all types and varieties of chicken can contract the fowl pox virus. Due to the greater surface area of these areas exposed to skin wounds, birds with wide wattles and broad combs are more likely to get pox lesions. Fowl pox has long been recognized as a common, enzootic disease of domestic chickens due to its distinctively dry, crusty skin lesions, which

are generally present on unfeathered areas of the comb and wattle, the face, and other gallinaceous birds (11,7, 12). In contrast, pigeon pox is a slowly spreading illness that affects both sexes, has a global distribution, and can be fatal to both sexes and all age groups. Poor flock health or parasitism may make the illness worse (9). Many years ago in Iraq, the pigeon pox virus was isolated and compared to the fowl pox virus in terms of both traits and experimental infection. In Baaquba, Diyala governorate, the virus was clinically found in several flocks of chickens and pigeons. This study's objective is to analyze some of its traits from

a virological and histological perspective.

Materials and Methods:

1.Sampel collection:

The current study was conducted at Diyala University's College of Veterinary Medicine from October 2022 to March 2023.

Twenty pigeons (*Columba livia domestica*) of various ages were gathered for this investigation from several bird markets in different areas of the Diyala governorate and twenty chicken *Gallus gallus* that were suspected of having pigeon pox and fowl pox. The experts were inspecting the pigeons and chickens and documenting the clinical signs presented as erosions, crusts, or nodules on the vent area and skin

of the head, particularly the cere, beak, and eyelids that the birds had, as well as their unique case histories as part of their profession. The samples were obtained immediately after the pigeons and chickens were euthanized. Following that, tissue samples were obtained and processed for a histological investigation from the affected regions of

2.Tissue preparation:

Tissue samples were extracted from various regions of the vent, eyes, wings, cere, and base of the beak shortly after being euthanized with a high dose of ketamine. Following that, tissue samples (4-6 mm thick) were

submerged in a 10% fixative formalin solution at room temperature for 24 hours before being processed. The samples were dehydrated in graded alcohol at room temperature for two hours (70% for two hours, 80% for two hours, 90% for two hours, and 100% for two hours), then submerged in xylene for two hours, followed by three hours in molten paraffin wax. The samples were then orientated and embedded in new paraffin (paraffin blocks). The blocks were sectioned with a microtome at a thickness of 5 μ m and examined on microscope slides. Routine stain hematoxylin and

eosin (H&E) staining protocols were used on the sections (13).

Results:

To further understand the impact of pox infection, histological analysis of a number of different tissue sections revealed that the majority of cutaneous lesions took the appearance of papules, pustules, or scabs. However, single or multiple nodular growths, as well as sometimes cauliflower-like growths, were also seen in certain cases. These lesions were found on the eyes, the beak, the legs, the vent, and the toes of the bird (Figure 1).



Figure 1, Naturally Infected Avian Poxvirus Suspected (Nodular Lesion) Chicken and Pigeon samples; A: Chicken, Pock lesions appeared on the head and around the eye. B, C and D: An adult Pigeons infected with poxvirus at different areas.

1.Histopathological results of cutaneous lesions of pigeons infected with avian pox

Histopathological examination revealed that cutaneous lesions were shown to cause distinctive histological changes in the epidermis of infected pigeons

(Figure 2). These changes included hyperplasia (acanthosis), which was caused by an increase in the size and number of cells in the stratum spinosum. The H&E stain demonstrated ballooning

degeneration of these cells, as well as the typical pale eosinophilic inclusion bodies in the cytoplasm (Figure 2&3).

Furthermore, the cytoplasm of some of the afflicted cells was unstained, which is also symptomatic of avian pox.

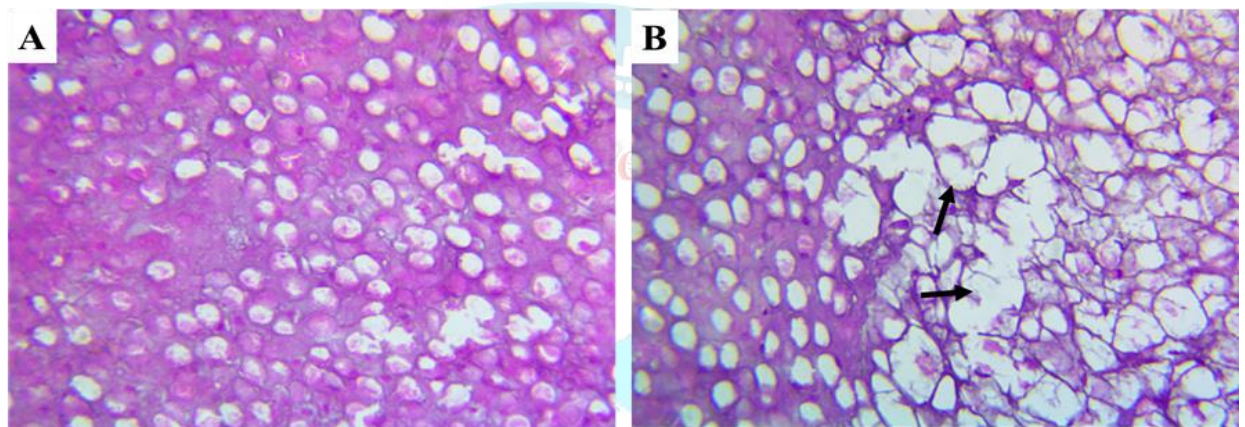


Figure 2: Photomicrographs illustrate the Histopathological section of changes in cutaneous lesions of pigeons infected with avian pox. A) showed hyperplasia of the keratinocytes, B) showed massive swollen keratinocytes with eosinophilic intracytoplasmic (Bollinger bodies) inclusion bodies (black arrows) that push the other cells to different sides. (40X, H&E.).

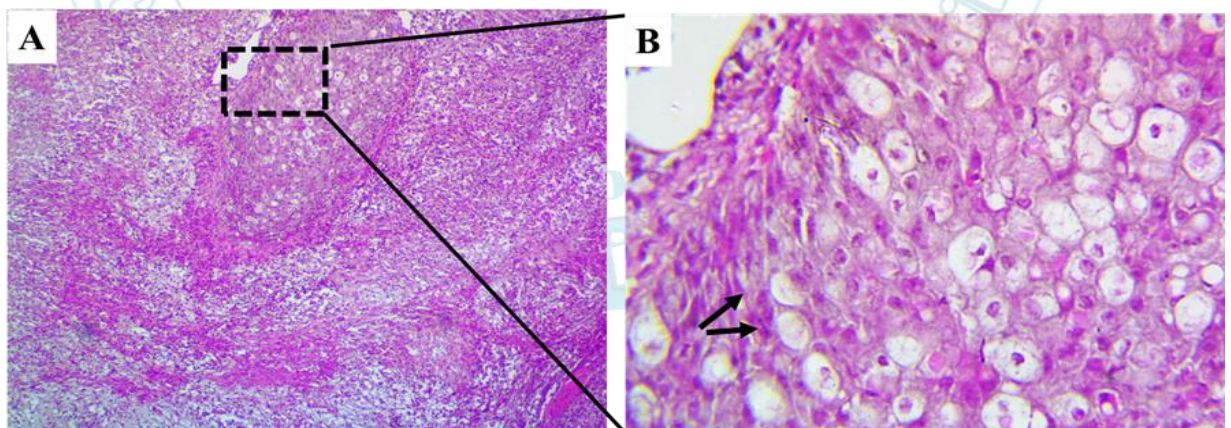


Figure 3: Photomicrographs illustrate the Histopathological section of cutaneous lesions of pigeons infected with avian pox. A, B) showed massive fibrosis and the keratinocytes appeared rounded and enlarged that possessed pleomorphic and hyperchromatic nuclei as

well as eosinophilic intracytoplasmic (Bollinger bodies) inclusion bodies. (A, 4X and B, 40X, H&E).

Pathogenic modifications were also found in the epidermis' basal cells, which were characterized by hypertrophy and hyperplasia respectively. Subcutaneous connective tissue proliferates vigorously, and polymorph mononuclear cells as well as macrophages migrate into the affected region (Figure 4). There were indications of fibrosis and the development of fibroblasts in several of the affected sites. As a result of deterioration, the stratified squamous epithelium had become swollen. The epithelial cells had swollen and rounded out, and they had been disconnected from one another in the process. Vast numbers of eosinophilic inclusions, also known as Bollinger bodies, can be seen in the cytoplasm of hyperplastic epithelial cells. These cells also show vacuolation (Figures 5).

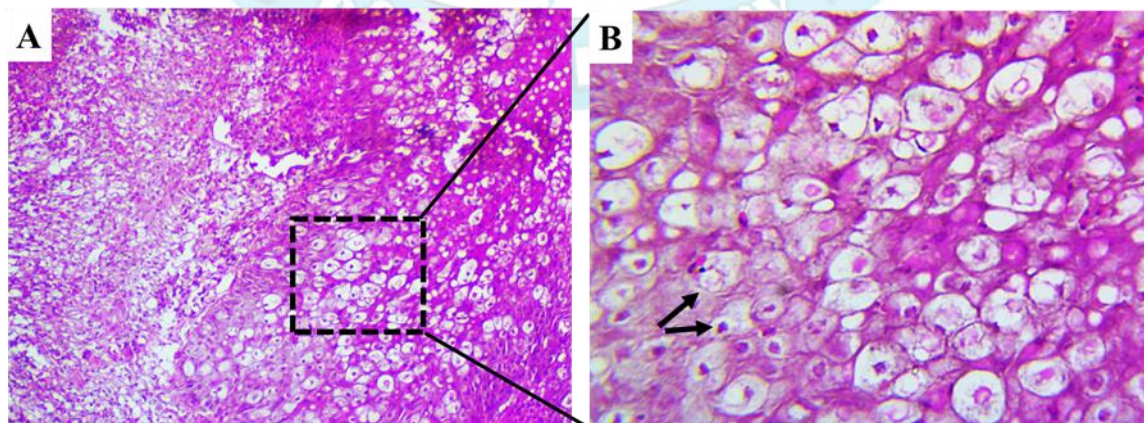


Figure 4: Photomicrographs illustrate the Histopathological section of cutaneous lesions of pigeons infected with avian pox. A, B) showed massive fibrosis and the keratinocytes appeared rounded and enlarged that possessed pleomorphic and hyperchromatic nuclei as well as eosinophilic intracytoplasmic (Bollinger bodies) inclusion bodies. (A, 10X and B, 40X, H&E).

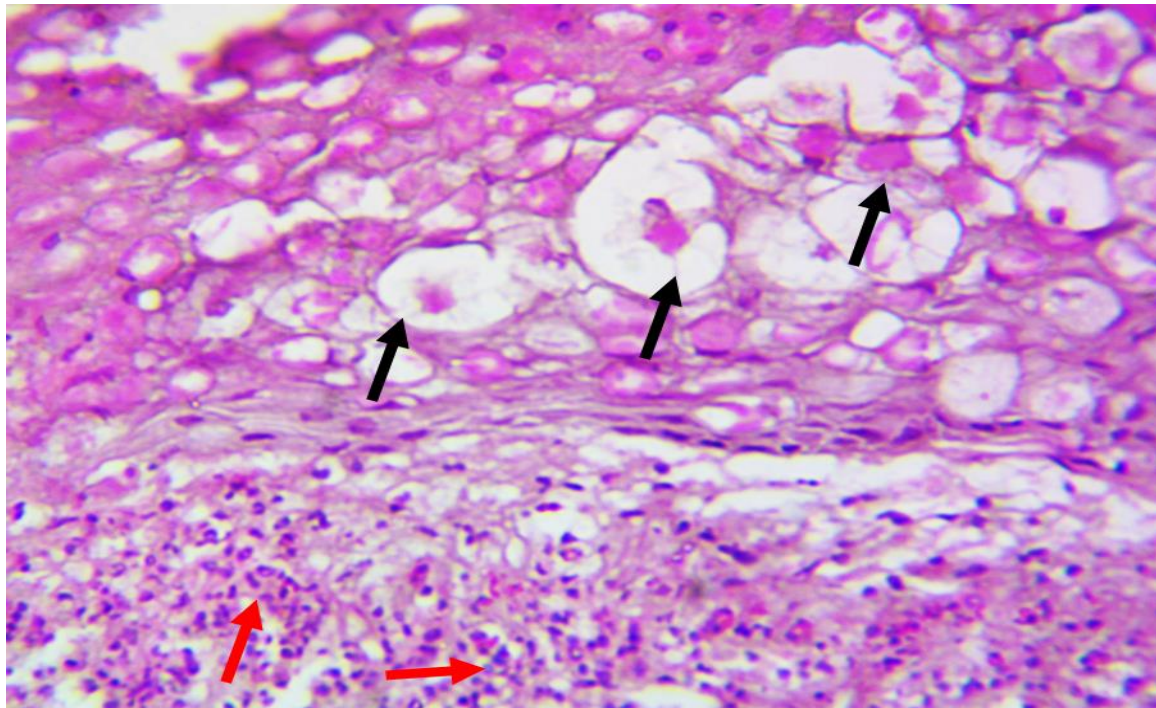


Figure 5: Photomicrographs illustrate the Histopathological section of cutaneous lesions of pigeons infected with avian pox. It showed massive swollen keratinocytes with eosinophilic intracytoplasmic (Bollinger bodies) inclusion bodies (black arrows) that push the other cells to different sides, it also showed infiltration with the inflammatory cells (red arrows). (40X, H&E).

2.Histopathological results of cutaneous lesions of chickens infected with avian pox

The histological changes that were studied on the sections obtained from the cutaneous

lesions of the head, combs, and wattles of infected chicken with avian pox typically had the appearance of warts, ranged in color from yellow to dark brown,

or took the form of scab-like lesions that were black. Analysis of the cutaneous lesions of chickens infected with the pox virus showed that the virus caused clear changes in the epidermal tissue, such as the formation of hyperplasia of stratified squamous cells with acanthosis, severe inflammatory exudation that included heterophils, macrophages, and lymphocytes, and, in some cases, it was noticed the presence of bleeding ulcers, especially the area that came from the head lesions (Figure 6). Additionally, it was also indicated some areas with numerous to moderately large eosinophilic intracytoplasmic and intra-keratinocyte inclusions, were represented as the Bollinger bodies (Figure 6).

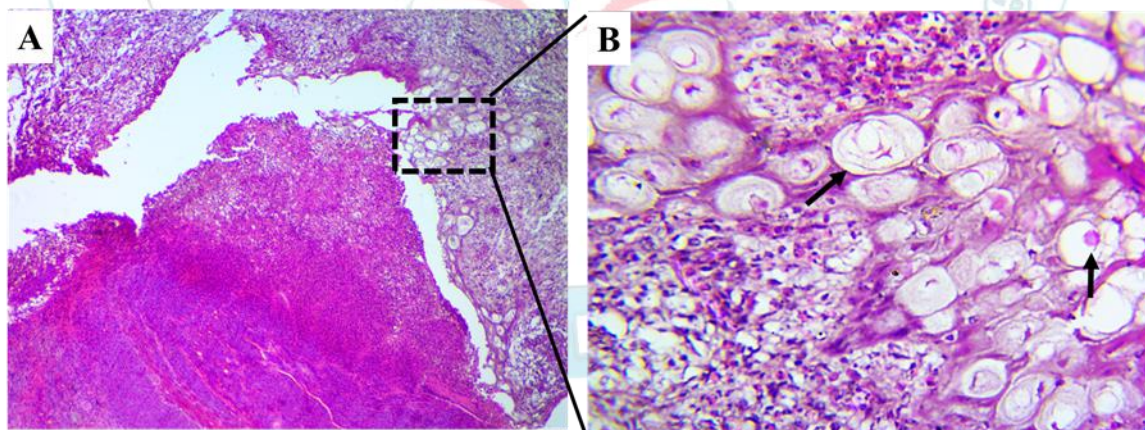


Figure 7: Photomicrographs illustrate the Histopathological section of cutaneous lesions of chickens infected with avian pox. It showed wollen keratinocytes with eosinophilic intracytoplasmic (Bollinger bodies) inclusion bodies and/or ring-like eosinophilic intracytoplasmic inclusions (black arrows) that push the nucleus to

one side and widespread growing of fibrous tissue, associated with polymorph mononuclear (PMN) cells. (A, 4X and B, 40X, H&E).

Further examination revealed that the lower layers of the epidermis exhibited hypertrophy as well as hyperplasia. There is a significant increase in the proliferation of subdermal connective tissue, which is also accompanied by an infiltration of macrophages and polymorphonuclear cells.

Discussions:

In order to show the severity of the cutaneous lesions caused by the avian poxvirus, histopathology was performed on pigeons and chickens. The keratinocyte degeneration and necrosis, as well as the hypertrophy and hyperplasia of epithelial cells in the basal and dermal layers of the epidermis, were the most obvious results of the current study's histological analysis.

Keratinocytes routinely display eosinophilic intracytoplasmic inclusion bodies (Bollinger bodies). This finding is consistent with that of Khan (14) who found similar outcomes in peafowl chicks; Mohan and Fernandez (9), Al-Ajeeli(15) and Hibl (16) who found comparable outcomes in pigeons; Ali (17) in Egyptian goose; Pledger, (18) who found similar outcomes in dove and also the same results were found in turkey Waziri (19); Yoksa,(20).

Cords and substantial clusters of hypertrophic and hyperplastic epidermal stratified squamous epithelium were visible upon

microscopic analysis of the nodular lesions. A dense fibroblastic stroma surrounded these clusters. The cytoplasm of the keratinocytes that created the lesions was foamy and vacuolated, and they were pale and swollen. Depending on the poxvirus strain or species of bird affected, these pathological signs are universal among birds (21, 14, 16). Bollinger bodies, which are large or ring-like eosinophilic intracytoplasmic inclusions, were seen in the tissues of both hens and pigeons with pox (15, 17, 16).

According to Hemanth, (22) Bollinger bodies are cytoplasmic structures that are usually

assumed to be the locations of viral particle multiplication.

According to Pledger (18) and Hibl (16), the presence of intracytoplasmic inclusion bodies made up of eosinophils in keratinocytes indicates a certain level of avian pox virus infection.

According to a theory, the early inclusions "represent the site of virus synthesis," whereas the later inclusions are thought to be residual or inadvertent lesions.

Numerous investigations (15, 17, 16) have backed up this line of reasoning. The fact that the huge vacuoles assumed to be in charge

of the development and assembly of virus particles are believed to

be late inclusions is another explanation for this.

These inclusions have the appearance of Bollinger bodies (22, 23). The necrosis of the cell was caused by the inclusions, which caused the cytoplasm of the cell to expand. Some of them had gaps that were clean, unstained, and rounded in the center. It has been suggested that these gaps and/or vacuoles, into which virus particles bud and assemble, are the late inclusions (17, 16, 20) and represent Bollinger bodies as shown in the tissue sections of both affected pigeons and chickens. The lesions' superficial epidermis was

ulcerated and had eosinophilic, amorphous keratinaceous crusts along with necrosis within each lesion was a single, spherical, dense viral inclusion that was made up of eosinophils. This finding broadly supports the work of other studies on avian pox (15, 17, 16, 23).

Conclusion:

Both pigeons and chickens are susceptible to the viral disease known as "avian pox." It is brought on by the Avipox virus, a member of the Chordopoxvirinae subfamily of the Poxviridae family. According to histological research, this viral infection led to severe pathological alterations in the cutaneous regions,

particularly affecting the epidermal tissues in pigeons and chickens.

5-Parker, Patricia G., Buckles, E. L., Farrington, H., Petren, K., Whiteman, N. K., Ricklefs, R. E., and Jiménez-Uzcátegui, G. "110 years of Avipoxvirus in the Galapagos Islands." Plos one 6.1 (2011): e15989.

References

1-Zhao, Kui, He, W., Xie, S., Song, D., Lu, H., Pan, W., and Gao, F. "Highly pathogenic fowlpox virus in cutaneously infected chickens, China." Emerging infectious diseases 20.7 (2014): 1200.

2-Weli, Simon C., and Morten Tryland. "Avipoxviruses: infection biology and their use as vaccine vectors." Virology Journal 8.1 (2011): 1-15.

3- Diallo, Ibrahim S., Taylor, J., Gibson, J., Hoad, J., De Jong, A., Hewitson, G., and Rodwell, B. J. "Diagnosis of a naturally occurring dual infection of layer chickens with fowlpox virus and gallid herpesvirus 1 (infectious laryngotracheitis virus)." Avian Pathology 39.1 (2010): 25-30.

4-Pattison, M., McMullin, P. F., Bradbury, J. M., and Alexander, D. J. "Poultry diseases, 6th Saunders Elsevier." (2008): 333-339.

6-MacLachlan, N. J., and E. J. Dubovi. "Adenoviridae." Fenner's Veterinary Virology, 5th ed.; MacLachlan, NJ, Dubovi, EJ, Eds (2017): 217-227.

7- Rebeka, S., Nazir, K. N. H., Rahman, M. T., Nipa, S. A., Rahman, M. M., Soma, S. S., & Rahman, M. B. (2019). Isolation and molecular detection of fowl pox and pigeon pox viruses for the development of live attenuated vaccine seeds from the local isolates. Journal of the Bangladesh Agricultural University, 17(2), 211-219.

8-Singh P, Kim TJ, Tripathy DN: Re-emerging fowlpox: evaluation of isolates from vaccinated flocks. Avian Pathol 2000, 29:449-55.

9-Mohan, M., and Trevor Francis Fernandez. "A case report of pigeon pox-histopathologic diagnosis." Veterinary World 1.4 (2008): 117.

- 10- Jarmin, Susan, Manvell, R., Gough, R. E., Laidlaw, S. M., and Skinner, M. A. "Avipoxvirus phylogenetics: identification of a PCR length polymorphism that discriminates between the two major clades." *Journal of General Virology* 87.8 (2006): 2191-2201.
- 11-Skinner, Michael A., Laidlaw, S. M., Eldaghayes, I., Kaiser, P., and Cottingham, M. G."Fowlpox virus as a recombinant vaccine vector for use in mammals and poultry." *Expert review of vaccines* 4.1 (2005): 63-76.
- 12- Delhon, Gustavo. "Poxviridae." *Veterinary Microbiology* (2022): 522-532.
- 13-Spencer, L., Bancroft, J., Bancroft, J., and Gamble, M. "Tissue processing." *Bancroft's Theory and Practice of Histological Techniques*. 7nd ed. Netherlands, Amsterdam: Elsevier Health Sciences (2012): 105-23.
- 14- Khan, Ahrar, Yousaf, A., Khan, M. Z., Siddique, M., Gul, S. T., and Mahmood, F. "Cutaneous form of pox infection among captive peafowl (Pavo cristatus) chicks." *Avian Pathology* 38.1 (2009): 65-70.
- 15- Al-Ajeeli, Karim S., Amer K. Al-azawy., and Ramzi Al-Ajeeli "Isolation of Pigeonpox Virus from Severe Infection of Pigeons in Diyala province: Virological and Histopathological Study." *The Iraqi Journal of Veterinary Medicine* 39.2 (2015): 72-78.
- 16- Hibl, Brianne M., Blackwood, R. S., Simons, B. W., and Collins, D. E. "Poxvirus Infection in a Colony of Laboratory Pigeons (*Columba livia*)." *Comparative Medicine* 69.3 (2019): 179-183.
- 17- Ali, AbdelMoneim, Mansour, S., Fathy, A., and Eid, A. "Detection of Avian Poxvirus in an Egyptian goose (*Alopochen aegyptiacus*)." *Global Animal Science Journal* 2.1 (2014).
- 18-Pledger, Alison. "Avian pox virus infection in a mourning dove." *The Canadian Veterinary Journal* 46.12 (2005): 1143.
- 19-Waziri, M. I., and L. Saidu. "Cutaneous and diphtheritic forms of avian pox infections in a juvenile ostrich." *Nigerian Veterinary Journal* 43.1 (2022): 76-83.

20-Yoksa, Daniel Thomas, Mohzo, D. L., Gapsiso, R. H., and Abba, Y. "Dry and diphtheritic pox in an adult turkey associated with suprainfection with Escherichia coli and Salmonella spp.: A case report." (2023).

21-Smits, J. E., Tella, J. L., Carrete, M., Serrano, D., and López, G. J. V. P. "An epizootic of avian pox in endemic short-toed larks (*Calandrella rufescens*) and Berthelot's pipits (*Anthus berthelotti*) in the Canary Islands, Spain." *Veterinary Pathology* 42.1 (2005): 59-65.

22- Hemanth, I., Amravathi, P., Sasidhar, B.N., Anand, K.A. and Sailaja, N. An outbreak of cutaneous form of avian pox in pigeons (*Columbia livia*). *Int. J. Sci. Environ.*, 3(4) (2014): 1484-1488.

23- Hartati, S., Untari, T., Nuraini, A. L., and Nururrozi, A. "A case report of outbreak avian pox virus from layer chickens and a pigeon in Yogyakarta, Indonesia." *Adv. Anim. Vet. Sci* 9.10 (2021): 1559-1563.

